Mouse Pathobiology & Phenotyping

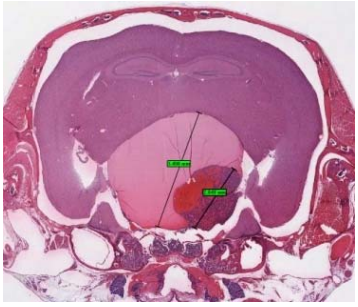

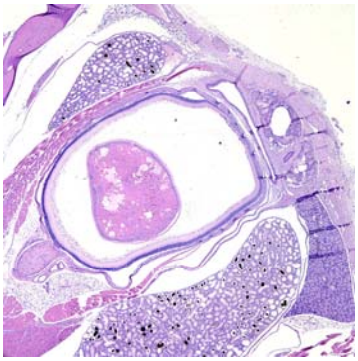

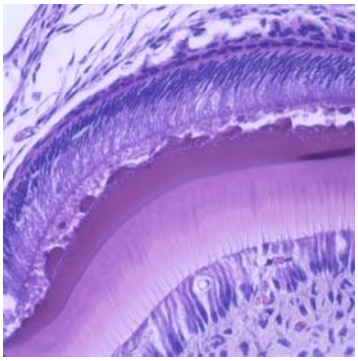

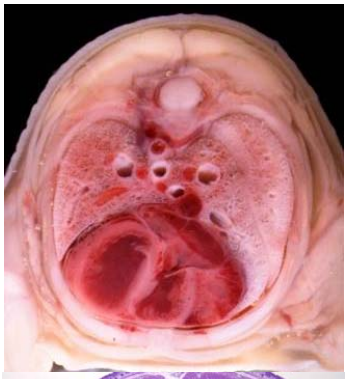

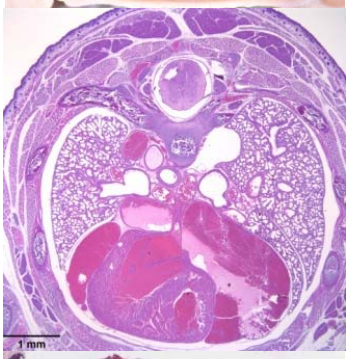

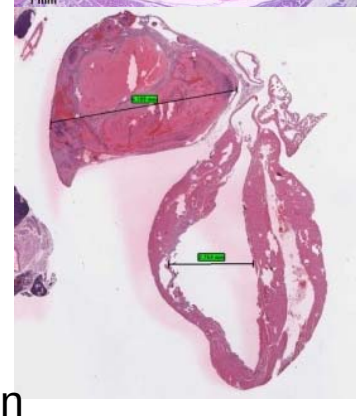

Short Course

2019

Lab Manual

5th edition

C Brayton, N Forbes McBean, J Watson
Department of Molecular & Comparative Pathobiology
Johns Hopkins University School of Medicine
Baltimore MD USA

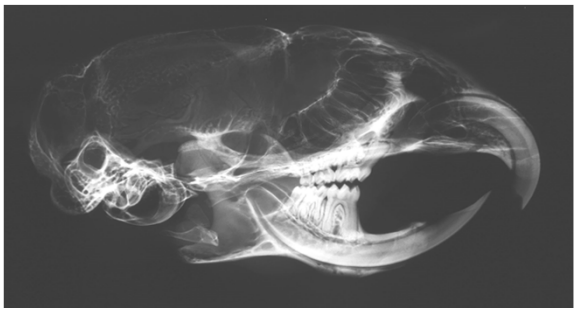

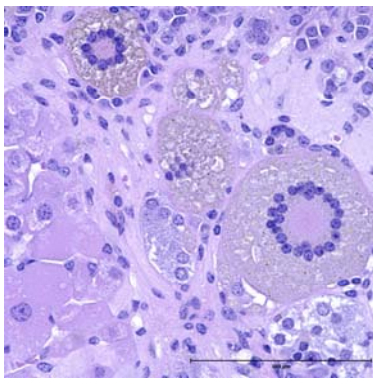

JHU Mouse Pathobiology and Phenotyping Short Course

Laboratory Manual
Practical Mouse Evaluation & Pathology

Contents

* ***ALL participants*** *should arrive promptly or early.*
* ***ALL participants*** *are expected to clean up after themselves, AND to assist in clean up of their work area.*

Graduate students *taking this course for credit MUST complete worksheets & hand them in for laboratory credit. (4 completed worksheets to receive full credit)*

How to Give a Mouse a Physical (And why you should)

Julie Watson MA Vet MB DACLAM

Background

- 1968 - Samuel Irwin - First Phenotyping Screen
  - Psychopharmacologia (Berl.) 13 222-257
- 1997 - SHIRPA stage I
  - Mamm Genome. 1997 Oct;8(10):711-
    Rogers DC, Fisher EM, Brown SD, Peters J, Hunter AJ, Martin JE
- 1997 - Jacqueline Crawley
  - Crawley,J and Paylor,R. Hormones & Behavior 197-211 (1997)
  - "What's Wrong with my Mouse?" Wiley-Liss 2000.
- Current - Websites:
  - EMPReSS (European Mouse Phenotyping Resource of Standardised Screens at Eumorphia
    http://www.eumorphia.org/EMPReSS/servlet/EMPReSS.Frameset
  - SHIRPA at MRC ENU Mutagenesis Program
    http://www.enu.har.mrc.ac.uk/facilities/mutagenesis/mutabase/

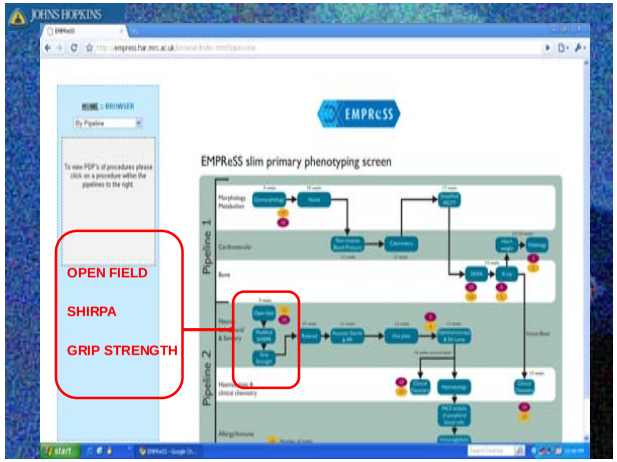

EMPRESS RECOMMENDATIONS FOR OPEN FIELD

- Noise and light standardized in husbandry room (upper rack 10x lux)
- Test in first half of light cycle
- Stabilize mice 30 mins before testing in anteroom
- Standardize light levels 150 -200 lux in testing chamber
- REF: Fentrop N, Wotjak CT (2000) Fiat lux! Spotting a common experimental problem, Poster presented at *Measuring Behavior The Netherlands 2000, 3rd International* Conference on Methods and Techniques

SHIRPA

- SmithKline Beecham Pharmaceuticals
- Harwell, MRC Mouse Genome Centre and Mammalian Genetics Unit
- Imperial College School of Medicine at St Mary's
- Royal London Hospital, St Bartholomew's and the Royal London School of Medicine
- Phenotype
- Assessment

Goals

1. Detect abnormalities likely to affect future phenotyping tests
   - Blindness
   - Physical defects
   - Deafness

http://mcp.bs.jhmi.edu/phenotyping-core

Some "Abnormalities" are Expected!

Age-related hearing loss & vestibular defects (<3m)	Blindness (rd1 gene)
Many 129 strains	C3H ,CBA
A/J	FVB*
C57BL/6J @12-18m OR EARLIER!	SJL, SWR
C57BR, C57L	BUB
DBA	NON
I, LP, NOD, ALR, ALS	P, PL

* Errijgers, V. (2006) FVB.129P2-Pde6b Tyr/Ant, a sighted variant of the FVB/N mouse strain suitable for behavioral analysis. *Genes Brain and Behavior* 0(0)

Environmentally Induced Variation May Affect Phenotype

- Husbandry methods (see John Crabbe, Science 1999)
- Noise (e.g. on age-related hearing loss, stress hormones, learning and memory)
- Group or single housing (e.g. on aggression, dominant or submissive behavior, stereotypy, isolation stress)
- Weaning age, fostering
- Diet (e.g. on cancer phenotypes, feminization)
- Medications (e.g on cancer phenotypes and gene expression, immunology, motor function)
- Light (light induced retinopathy) (circadian rhythm)
- Infections (physical health, immunology)
- Odors (personnel, animals, equipment used on other animals)
- Bedding (nest building, protection from drafts)
- Water (acid water)
- Personnel, handling, etc.

Other Pitfalls

- How big is the gene effect compared to the background variability?
  - Background strain not inbred F1's, N2's, chimaeras (!) … 2.5 years to congenic
  - Don't have comparable controls
- Do you have enough animals? (10-12 ea. WT het -/- M&F)
- Statistical analysis ? - ordinal data
- Genotyping reliability – Transnetyx estimates HH 10% gene not present.

Assuming the phenotype is real …

- Presence of abnormal behaviors, e.g. motor or neurological deficits
- Absence of normal behaviors
- *Suggests* further testing





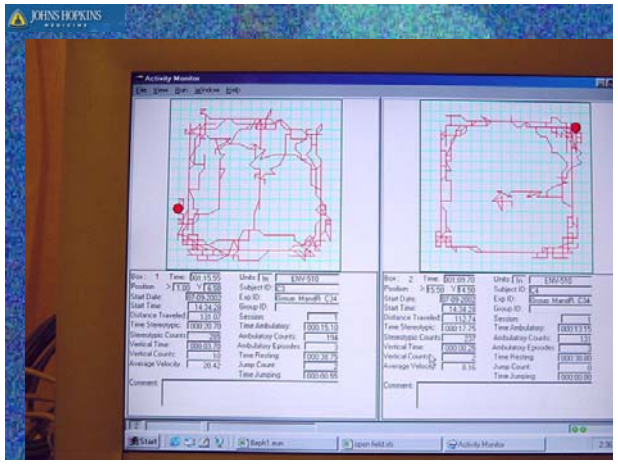



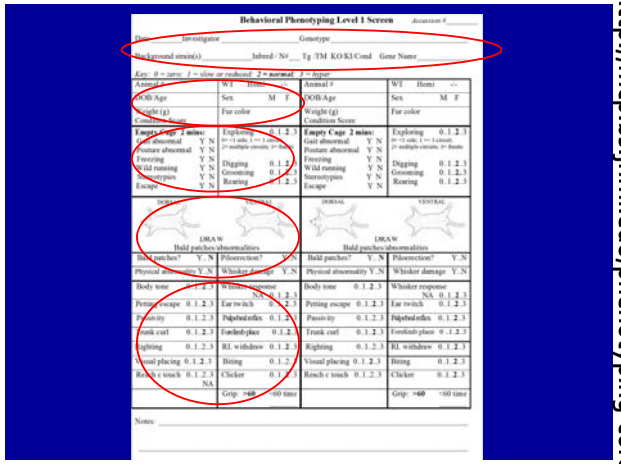

Worksheet in Lab Manual

http://mcp.bs.jhmi.edu/phenotyping-core

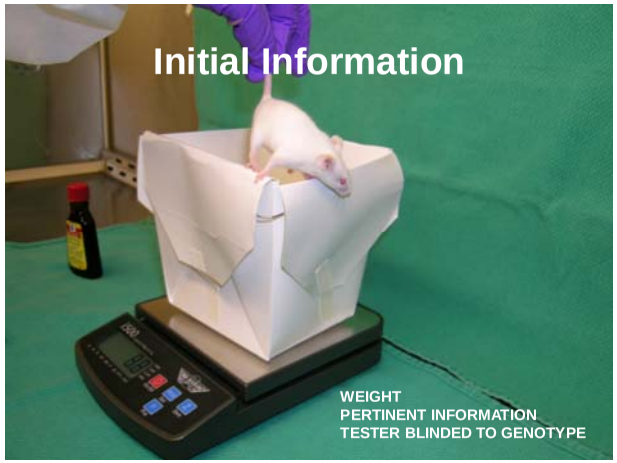

Observation in Cage

- Gait, posture, general appearance: do the mice look as expected?

- Picture Credit: Maria Lorenzo

Observation: other abnormalities

Observation in Cage

- Gait, posture, general appearance: do the mice look as expected?
- Are normal behaviors present?
  - Exploring, thigmotaxis, digging, grooming, rearing

Rearing/Escape/Thigmotaxis

Digging

Subtle Deficits

Limited Rearing

http://mcp.bs.jhmi.edu/phenotyping-core

Observation in Cage

- Gait, posture, general appearance: do the mice look as expected?
- Are normal behaviors present?
  - Exploring, thigmotaxis, digging, grooming, rearing
- Are abnormal behaviors present?
  - seizures, pruritus, motor deficits, stereotypies

Obvious Motor Deficits

- Picture Credits: Cory Brayton and Nadine Forbes

Abnormal Behavior

Vestibular/infarct

- Video credit: Nathan Pate

Abnormal Motor Behavior: Dermatitis

- Picture credit: Dawn Ruben

Stereotypy

Physical Exam

- Pick up, record abnormal physical features
  - Whisker loss, bald patches
    - barbering, fighting, dermatitis, parasitism
  - Unkempt haircoat, piloerection
    - sick mouse
  - Eyes, legs, tail
    - Genetic/congenital defects, fighting, parasitism

Normal Whiskers

Whisker loss

Effects of Whisker Removal

- Aggression tests – decreased early withdrawal
- Decrease in flight
- Decrease in freezing

- Effect of whisker removal on defensive behavior in rats during early ontogenesis
- Shishelova,
- Neuroscience and Behavioral Physiology, 36 (8) Oct. 06, 883-888

Barbering

Ref. Kalueff et al. Behavioral Processes 2005

- Usual: barbering by socially dominant mouse
  - Requires cooperation
- All mice in cage may barber if e.g. overcrowding stress
- More social barbering = less physical aggression
- Whiskers are important
  - Bitten off, not pulled out
  - Used for object & texture discrimination
  - Exploration, balance and orienting

Tests of General Reactivity

Four Tests

- Response to approach
- Body tone
- Petting escape
- Passivity

Normal Response to Approach

Normal Body Tone

High Body Tone

Petting Escape

Exacerbated Escape Attempts

Passivity

Tests of Postural Reactions and Reflexes

- Trunk curl
- Righting reflex
- Forelimb proprioceptive positioning
- Rearlimb withdrawal

http://mcp.bs.jhmi.edu/phenotyping-core

Trunk Curl



Trunk Curl (abnormal)

Righting Reflex

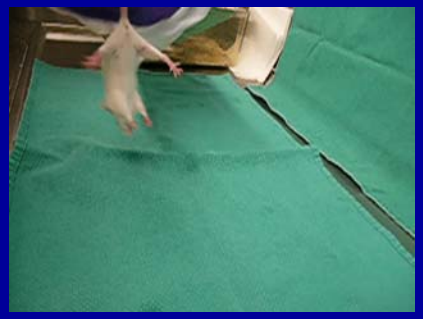

Proprioceptive Positioning

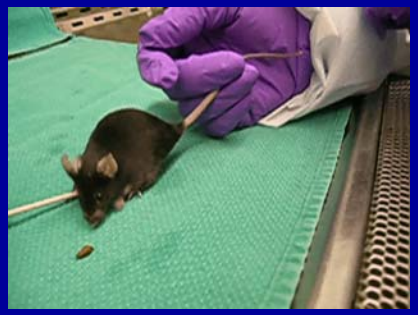

Withdrawal – Fast (B6)

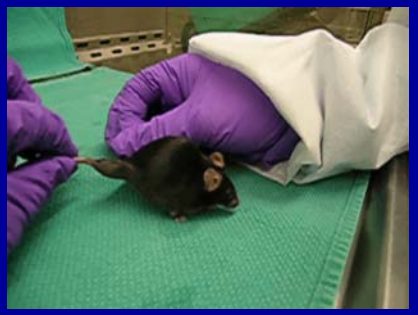

Withdrawal – Slow (129)

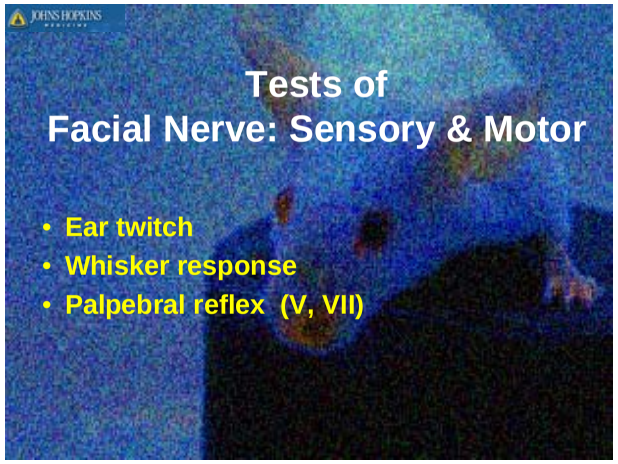

Ear Twitch

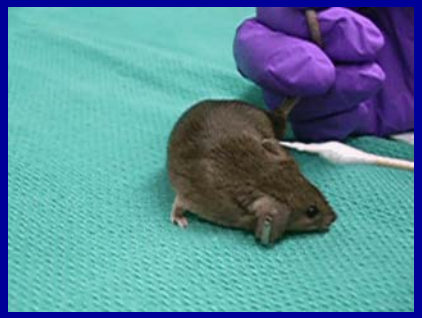

Whisker Response

http://mcp.bs.jhmi.edu/phenotyping-core

Palpebral Response

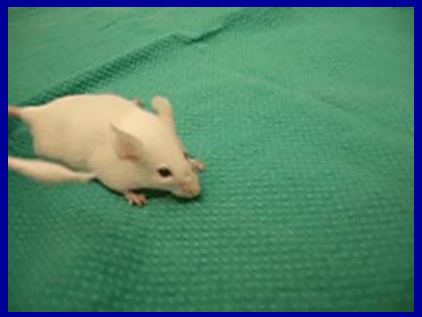

Sight: Visual Placing

Blind Mouse – Tactile Placing

Virtual Sight Test By Optokinetic Tracking

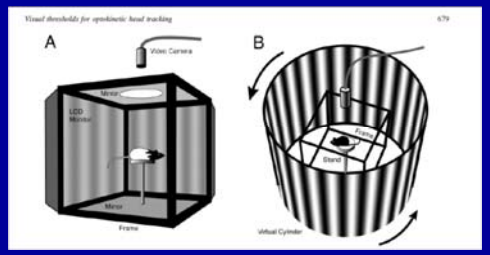

- Caroline Thaung,, Karen Arnold alan J. Jacksonb and Peter J. Coffey Presence of visual head tracking differentiates normal sighted from retinal degenerate mice

-RM Douglas, Prusky et al. Independent Visual Threshold Measurements in the 2 eyes of freely moving rats and mice using n a virtual reality optokinetic system. Visual Neuroscience 2005 22: 677-684

Optokinetic Tracking in Action

http://www.cerebralmechanics.com/OM/Video.html

- Slow head and body rotation when grating is present.
- No tracking when the screens are gray.
- The red cursor is repositioned by the experimenter to keep the center of rotation centered on the head.
- The mouse is untrained and free to move on the platform

Sight Needed for Morris Water Maze Test for Learning & Memory

Sight Needed for Tests of Anxiety

- Elevated Maze



- Light Dark Box



- Visual Cliff

Sight Even Needed for Motor Performance

M. P. McFadyen, G. Kusek, V. J. Bolivar, L. Flaherty (2003)
Differences among eight inbred strains of mice in motor ability and motor learning on a rotarod
Genes, Brain and Behavior 2 (4), 214–219.

- C3H/HeJ mice (with retinal degeneration) compared with (Pdeb+) mice (without retinal degeneration) on the rotarod
- The sight-impaired C3H mice stayed on the rotarod longer than did their sighted Pdeb+ partners

Hearing Test

Clicker

http://mcp.bs.jhmi.edu/phenotyping-core

Tests That May be Affected by Hearing Loss

Cued Fear Conditioning

For learning and memory

Prepulse Inhibition

For sensorimotor gating

Other Tests

- Provoked Aggression
- Grip Strength

Test for Provoked Aggression

Grip Strength Normal

Grip Strength Abnormal

Grip Strength Apparatus

Images from EMPRESS



Acknowledgements

- Janice Clements
- Christian Newcomer
- Jacqueline Crawley
- Michela Gallagher
- Cory Brayton
- Nadine Forbes

Questions?

http://mcp.bs.jhmi.edu/phenotyping-core

JHJW Modified SHIRPA Summary

This screen should take about 10 minutes per mouse and provides a basic evaluation for abnormal behaviors, and absence or reduction in normal behaviors or reflex responses. Abnormalities in this basic screen can direct more in-depth testing.

1. Condition Score: **(1-5)**
   1 = **Emaciated** vertebra distinctly segmented. Little or no flesh cover
   2 = **Thin** – segmentation of vertebra evident. Skeletal structure: dorsal pelvic bones are readily palpable
   3 = **Normal.** Mouse is well-conditioned. Vertebrae and dorsal pelvis not prominent; palpable with slight pressure
   4 = Mouse **over conditioned**. Vertebrae palpable only with firm pressure
   5 = Mouse is **obese.** Bone structure disappears under flesh and subcutaneous fat

2. Gait abnormal **(Y or N)** What is abnormal? Hopping rather than running, exaggerated limb movements, limbs kicking out or dragging, lack of bilaterally symmetrical movement, uneven cadence, unable to move in a straight line, loss of balance

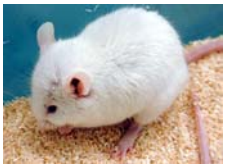

3. Posture abnormal? **(Y or N)** What is abnormal? Body rounded or hunched, Head tilt or other head or body asymmetry, tail dragging or held rigid. Picture shows a rounded (abnormal) position.

4. Body Tone: **(0-3)** Hold the mouse by the tail base on a hard surface. With 2 fingers gently press down over the mid dorsum. Normal tone: will resist depression somewhat – not allowing depression to the floor. 0 = flaccid; 1 = allows depression to floor; **2 = allows some flattening;** 3 = hunches back to completely resist compression

5. Petting Escape: **(0-3)** Hold the mice by the tail base on a hard surface. With finger and thumb stroke down the flanks (sides) of the mouse from front to back. 0 = no reaction; 1 = difficult to elicit escape response; **2 = easy to elicit escape response;** 3 = Difficult to test because of spontaneous escape attempts

6. Passivity: **(0-3)** -Hold the mouse by the tail and place front paws on the edge of the cage top. Normal mice will promptly climb up to the top of the cage. Falling off or hanging without climbing is abnormal. This test is often used to evaluate drugs for sedative effects.
   0 = falls; 1 = delayed or unsuccessful attempt to climb up; **2 = normal;** 3 = hyperactive.

7. Trunk Curl: **(0-3)** Suspend mouse from tail for 15 seconds and monitor for curling of trunk. Normal response is curling up laterally to at least horizontal. 0 = zero or abnormal response e.g. hindlimb clasping; 1 < 90° curl; **2 = curls to 90° or more;** 3 = climbs up tail.

8. Righting: **(0-3)** – Hold mouse by tailbase. Hold your other hand flat with thumb up and little finger down to provide a vertical surface. Bring the dorsum (back) of the mouse to the back of your hand. Once the normal mouse feels the surface of your hand, it will quickly flip over so as to climb up the hand. 0 = does not right itself; 1 = struggles to right itself; **2 = rights itself;** 3 = hyperactive.

JHJW Modified SHIRPA Summary

9. Visual Placing/Reach Touch: **(Y or N)** Hold the mouse by the tail and lower it slowly, steadily, toward the wire bar lid on top of the cage. A visual mouse will start to reach or struggle down towards the surface well in advance of touching it. A blind mouse will not reach out until forelimbs or whiskers touch. This is difficult test to perform, principally because the whiskers of most mice are very long and may touch without you seeing them in which case you could interpret a blind mouse as sighted.

10. Whisker response: **(0-3)** The vibrissae are stimulated using a 'teased out' cotton tipped applicator. This test can be difficult to elicit consistently because vibrissae difficult for you to see, or mouse may see the approaching stimulus. Touching vibrissae should elicit a response: either a cessation of "whisking" (continual movement of whiskers), or a responsive nose quiver, which may be subtle. 0 = no response; 1 = difficult to elicit a response; **2=normal response;** 3= hyperactive response

11. Ear Twitch: **(0-3)** Using a teased-out cotton tipped applicator, gently touch the ear pinna. Watch closely! A normal response is a rapid ear twitch. 0 = no response; 1 = difficult to elicit response; **2 = an obvious response;** 3 = hyper repetitive response.

12. Palpebral reflex: **(0-3)** Using a teased-out cotton tipped applicator, gently touch the cornea. 0 = no reaction; 1 = slow blink; **2 = quick blink;** 3 = hyper repetitive blinking.

13. Forelimb place: **(0-3)** Hold the mouse by the tail on a hard surface. Using the wooden applicator, gently move a forelimb out to the side. The normal mouse will immediately return the limb under the body. 0 = Leg stays where placed; 1 = slow or incomplete return; **2 = Promptly returns leg to** normal position; 3 = hyperactive response.

14. Withdrawal: **(0-3)** Hold the mouse by the tail on a hard surface. Pick up the hindfoot and pull the limb out at a 45° angle until it is stretched then let go. A normal mouse will rapidly return the hindlimb to normal position. 0 = Leg drops to ground and doesn't return to normal position; 1 = slow to return; **2 =rapid return;** 3 = hyperactive response.

15. Biting: **(Y or N)** A wooden stick is placed in front of the mouse's mouth. The most common reaction is to ignore or turn away from the stick. This should be scored as no biting, or biting.

16. Clicker (hearing test): **(0-3)** Hold mouse by the tail base on a hard surface. After a moment of silence & calm, use the clicker once, observing closely for a Preyer response (ear flick), or stop response (head motionless briefly). Be careful not to allow the mouse to see you activate the clicker. Repeated clicks are often ineffective. 0 = no response; 1 = difficulty in eliciting response; **2 = immediate response;** 3 = abnormal response (seizures, hyperactive escape, etc)

17. Grip: **(# sec)** Place mouse on wire bar lid 1-2 feet above ground. Start the timer for 60 secs, shake grid gently then rapidly flip over the wire bar lid over. <60 secs is abnormal; **normally mice hold on upside down easily for 60 secs.**



PHENOTYPING CORE SPECIMEN COLLECTION

N Forbes July 2012 – Rev 2019 CB

1

OUTLINE

- Survival Bleed (facial vessels)
- Terminal Bleed, anesthetized mouse
  - Cardiocentesis
  - Confirm death
- Blood Glucose
- Fecal Occult Blood
- Urinalysis
- Additional FYI

2

SURVIVAL FACIAL BLEED

Aim: obtain blood samples from the facial vessels of a mouse.

- **Required:**
  1. 26 gauge needle, short (1/2 inch or less), or 3-4 mm lancet;
  2. Small blood collecting tube;
  3. Clean work surface;
  4. Alcohol pad;
  5. Mouse.
- *Not required: Anesthesia (if ACUC approved).*

3

SURVIVAL FACIAL BLEED (CONTINUED)

- Pick up the mouse, holding tail near base.
  - Use dominant hand (right for most people)
- Place the mouse on the wire bars of the cage.
- Cup the free hand over the mouse, and scruff it **firmly** using the thumb and first finger.
  - NOTE: It is **critical** to hold a lot of skin; so much that it looks like the mouse's tongue protrudes. Not so tight as to kill the mouse.
- You can tuck the tail between your last two fingers.
- You should now have the mouse gently and securely restrained in your non-dominant hand, and be able to pick up the mouse.

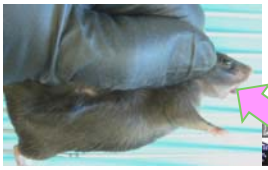

4

SURVIVAL FACIAL BLEED (CONTINUED)

- Locate the hairless freckle on the side of the jaw.
  - If you cannot see the freckle, draw a mental line along the lateral face at the level of the nose. Draw another mental perpendicular line down from between the eyes and ears. Where those lines intersect is the "sweet spot."
- Pick up the lancet or needle with your free hand.
- **Prick.** If using a needle, go in *only* to the depth of the bevel.
- Quickly discard the sharp into the sharps container, and pick up your collection tube.
- Collect 4-7 drops of blood.
- Press gently/firmly with alcohol pad to stop bleeding.
- Release the mouse into cage when bleeding has stopped.

5

SURVIVAL FACIAL BLEED (CONTINUED)

6

TERMINAL BLEED

AIM: Terminal maximal blood collection by Cardiocentesis

- **Required:**
  1. Deeply anesthetized mouse;
  2. 1cc syringe/22-25g needle,
  3. Blood tubes
     - With anticoagulant for CBC, plasma etc;
     - Gel separator tubes preferred for serum, plasma;
     - Eppendorf, for practice…

7

TERMINAL BLEED

- Anesthetize mouse.
- Orient animal ventrum (belly) up with nose toward your non-dominant side.
- With non-dominant hand, brace the animal; abduct (spread) forelimbs for maximum exposure of thorax.
- With dominant hand, feel xiphoid process; keep eyes fixed on that spot.
- Insert needle/syringe just left of xiphoid at about 30o angle, aiming toward dorsal neck.
- Pull back slightly on the plunger. If blood is absent, rotate/reposition needle/ syringe slightly (in/out, side to side) WITHOUT pulling completely out of chest.
- As blood enters syringe continue pulling back gently.
- Depending on the size of the mouse, you should be able to remove 500-1000ul of blood, sometimes more.
  - Mouse blood clots quickly (within 15-20 seconds).
- Remove needle and gently eject blood into tube.

8

TERMINAL BLEED

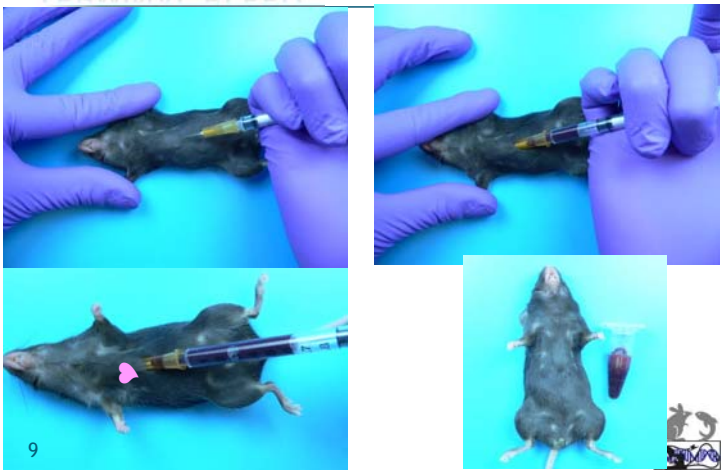

9

BLOOD GLUCOSE MEASUREMENT

- Aim: Measure whole blood glucose using One Touch or Accuchek Glucometers
- Required:
  1. Small pipette,
  2. Small weigh dish,
  3. Glucose strip, (check expiration dates)
  4. Glucometers,
  5. Mouse.

10

BLOOD GLUCOSE (ONE TOUCH)

- With small pipette, place **1-2 drops** of un-clotted blood into the small weigh dish.
- Orient the glucose strip so the white bars face you.
- Press the white bar end firmly into the top slot of the meter.
- Wait 8-10 seconds until the LSD screen shows **"Apply Blood".**
- Touch the free end of the strip to th dish.
- Record results.
- Pull strip out of slot and discard.
- The meter will turn off automaticall

11

BLOOD GLUCOSE (ONE TOUCH)

12

BLOOD GLUCOSE (ACCUCHEK)

- With small pipette, place 1-2 drops un-clotted blood into the small weigh dish
- Slide and release strip ejector (between "M" and "S")
- Test strip will appear
- Touch free end of strip to drop of blood in weigh dish.
- Record results

13

FECAL OCCULT BLOOD

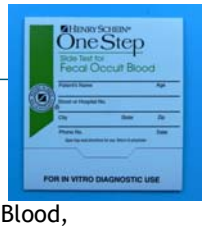

- **Aim: detect blood in feces**
- **Required:**
  1. Test Slide (Envelope) for Fecal Occult Blood,
  2. Smearing Stick,
  3. Developer,
  4. Feces.

AKA: guaiac test

- *When hydrogen peroxide (developer) is dripped on to guaiac paper, it oxidizes alpha-guaiaconic acid to a blue colored quinone.*
- *Heme catalyzes, accelerates reaction → rapid change*

14

FECAL OCCULT BLOOD (DEMONSTRATION)

- Retrieve 2 soft fecal pellets from cage.
- Touch 1 pellet to blood in the weigh dish (= 'positive' for this demonstration).
- Open Hemoccult envelope (side that reads "For in vitro Diagnostic Use") Use wooden applicator to smear both pellets onto circles I and II.
- Close envelope, Wait 2 minutes.
- Open the back of the envelope and apply 2 drops developer on each smear.
- Rapid change to Blue is a positive result, indicating presence of blood (heme).
- No or very slow change indicates absence of blood/heme.

15

FECAL OCCULT BLOOD

Positive Blue

Negative

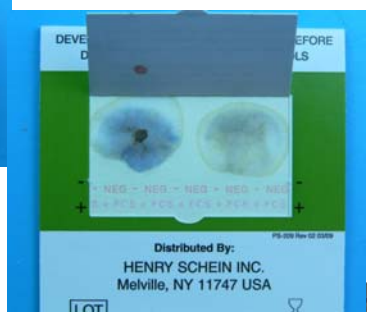

16

URINALYSIS

Aims:

1. Collect mouse urine.
2. Measure urine specific gravity.
3. Test with dipstick (chemstrip).

- **Required:**
  1. Veterinary refractometer,
  2. 96 well microtiter plate, clean,
  3. Small pipette.
  4. Mouse in container (opaque & small is good).

17

URINALYSIS

- Place plate(s) (or sand or foil) in container to cover the bottom;
- Place mouse in container undisturbed 20-30minutes.
- Mouse may have urinated, or may urinate as it is lifted from the cage - be sure to hold it over the wells.
- Pipette urine from well .
- **Specific gravity by refractometer:**
  - Place 2 drops on the glass plate and close top,
  - Read Specific Gravity through the eye viewer.
- **Specific gravity, glucose, protein by chemstrip dipstick**
  - Place 1 drop on each test pad,
  - Compare pad color with the guide on chemstrip container.
- **Record results**
  - Compare SG of refractometer vs dipstick.

18

URINALYSIS







19

IN CONCLUSION 1

- Useful data from inexpensive tests.
- Which glucometer do you prefer?
  - ❑ Accuchek? Your result: _____.
  - ❑ One touch? Your result: _____.
- Why?_____.
- Which method do you prefer for urine SG?
  - ❑ Refractometer Your result: _____.
  - ❑ Chemstrip Your result: _____.
- Why ? _____.

20

IN CONCLUSION 2

- **Weighing** is not emphasized in this lab for practical reasons, but is another source of good inexpensive data.
- Which procedures are useful to your studies?
  - ❑ Growth curves (from body weights)
  - ❑ Bleeding
  - ❑ CBC
  - ❑ Chemistry
  - ❑ Urinalysis
  - ❑ Fecal Occult blood

❑ Other:

21

FYI COLLECTION OPTIONS - MICE

- https://norecopa.no/films-and-slide-shows/mouse
- https://www.idexxbioanalytics.com/hubfs/Discovery-Resource%20Materials/Patho/Blood%20Sample%20Coll%20Guide%20v6.pdf etc

	Max blood volume
Retroorbital SINUS (retrobulbar)	<0.5ml?
CHIN Submental/ Inferior labial vv	<0.2ml
Lat Saphenous	<0.2ml
CHEEK Submandibular/Facial Vein Superficial temporal ?	<0.05ml (50ul) <0.5ml?
Tail tip (amputation/ mixed blood)	<0.2ml
Cardiac /terminal	1ml /more?
Caudal Vena Cava /terminal	~1ml

22

FYI WEEKLY BLOOD COLLECTIONS

- Raabe et al 2011.
- B6 male /female, 10-14wo, n ~20/g
  - 15%, 20%, or 25% of estimated total blood volume (TBV) collected once weekly x 6 wk.
  - Fentanyl / retrobulbar

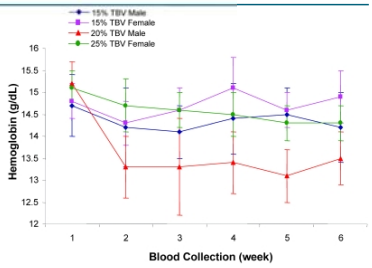

https://www.ncbi.nlm.nih.gov/pmc/articles/PMC3189672/

EXPECT REGENERATIVE RESPONSES BUT:

- Up to 25% TBV was collected once weekly from female mice x 6 wk;
- Up to 15% TBV was collected once weekly from male mice x 6 wk;
- **without** weight loss, behavioral changes, or clinically significant anemia.

23

APPROXIMATE BLOOD COLLECTION VOLUMES

- https://norecopa.no/films-and-slide-shows/mouse
- https://www.idexxbioanalytics.com/hubfs/Discovery-Resource%20Materials/Patho/Blood%20Sample%20Coll%20Guide%20v6.pdf
- Circulating blood volume (CBV) approximately 55-70 ml/kg of body weight

Body wt g	~CBV ml	1% q 24hr	7.5% q7d	10% q2-4w
20	1.10 - 1.40	11-14ul	90-105ul	110-140ul
25	1.37 - 1.75	14-18ul	102-131ul	140-180ul
30	1.65 - 2.10	17-21ul	124-158ul	170-210ul

24

FYI: COLLECTION SITE MATTERS

- CBC
  (Also FACS, chem)

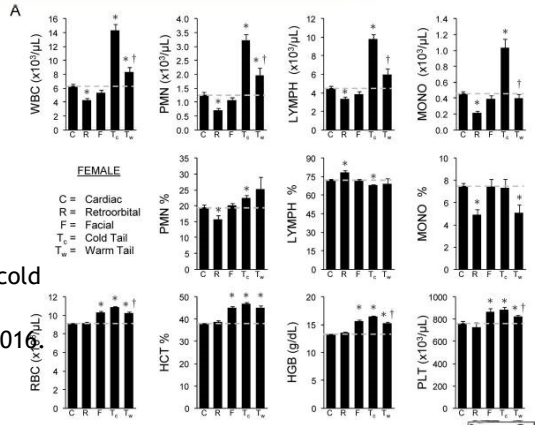

* Significant difference vs cardiac.

† Significant difference vs cold tail

Hoggatt et al. 2016.

25 https://www.ncbi.nlm.nih.gov/pubmed/26644183

FYI: COLLECTION SITE MATTERS

- CBC
  (Also FACS, chem)

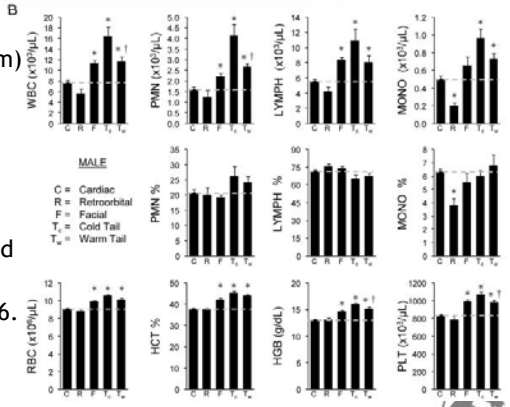

* Significant difference vs cardiac.

† Significant difference vs cold tail

Hoggatt et al. 2016.

26 https://www.ncbi.nlm.nih.gov/pubmed/26644183

FYI: COLLECTION SITE MATTERS ?

- HEMOLYSIS ☹

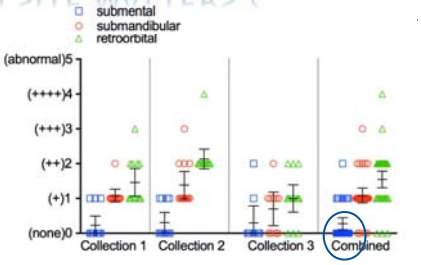

- CLOTS ☹

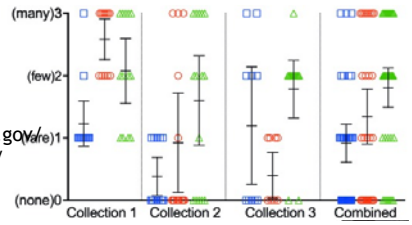

- Regan et al 2016
  https://www.ncbi.nlm.nih.gov/pmc/articles/PMC5029828/

27

FYI BLOOD COLLECTION SITES

- RB Retrobulbar; FV Facial vessels
  - Up to 0.5ml ? (~ operator experience/expertise)
  - Which facial vessels???
  - Arteries usually run with veins..
- Tail vessels, Saphenous vessels
  - <0.2ml
  - Effects of squeezing ☹ aka milking leg, tail: expect hemolysis, ⇧CK, ⇧LDH, ⇧K etc…
- Cardiac/terminal
  - Up to 1.5ml ? (~ operator experience/expertise)

28

FYI 'FACIAL' BLOOD COLLECTIONS

- Facial Vessels
  - Veins with arteries
  - Cheek (low)
    - Facial vessels ('submandibular v'?)
  - Cheek (high)
    - Inferior palpebral or transverse facial vessels?
    - Superficial temporal and maxillary
  - Chin
    - Submental or Inferior labial?

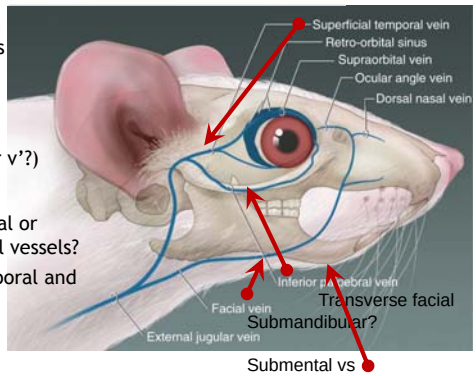

Image from Yardeni et al. 2011 – retroorbital injection technique
https://www.ncbi.nlm.nih.gov/pmc/articles/PMC3158461/

FYI FACIAL VESSELS

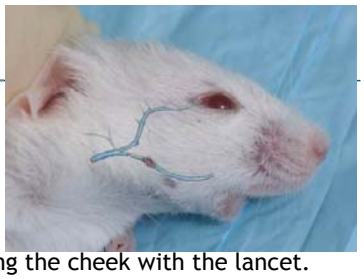

- Golde et al 2005
- Which vessels ?? →
- 'submandibular' ?
- Arteries with veins …
- Fig 3a: Positioning and poking the cheek with the lancet.
- →

30 A rapid, simple, and humane method for submandibular bleeding of mice using a lancet https://www.nature.com/articles/laban1005-39

SUBMENTAL OR INFERIOR LABIAL VEIN?

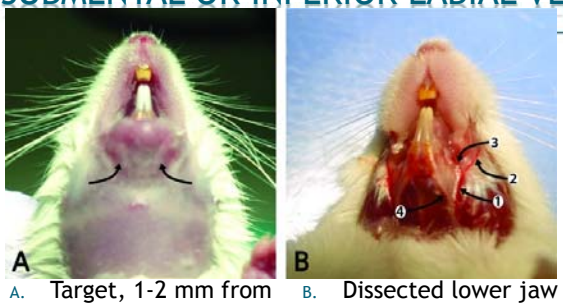

CHIN

A. Target, 1-2 mm from midline, for vascular access (arrows) mouse.

B. Dissected lower jaw 1. and 2. facial v.; **3. inferior labial v.; 4. submental v.**

- Regan et al 2016
  - https://www.ncbi.nlm.nih.gov/pubmed/27657712 Comparison of Submental Blood Collection with the Retroorbital and Submandibular Methods in Mice (Mus musculus).
- Constantinescu & Duffee 2017
  - https://www.ncbi.nlm.nih.gov/pubmed/29256364 Comment on anatomy

31

FYI RETROORBITAL VENOUS SINUS OR PLEXUS?

- For blood collection, or injection.
- (AFTER Approval by IACUC/ethical committee)

A. Medial canthus
B. Lateral canthus
C. Dorsal to the eye

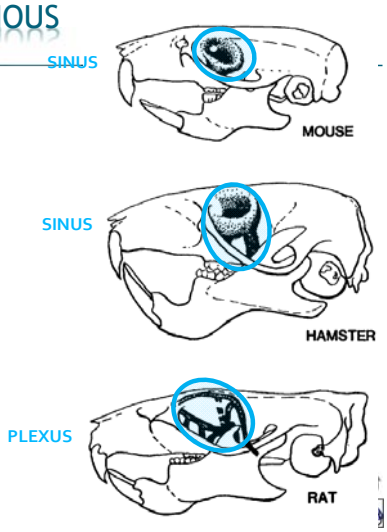

Timm. 1980. Synapse.

FYI RETROORBITAL SINUS

(aka Retrobulbar)

- Collections
  - Anesthesia?
  - Adults up to ~.5ml ?
  - with approval (& experience)
- Injections
  - Anesthesia?
  - Adults up to ~150ul?
  - with approval (& experience)

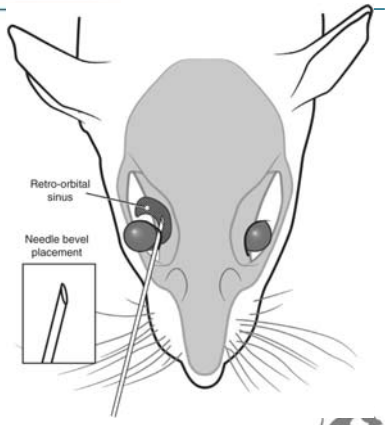

Image from Yardeni et al. 2011 – retroorbital injection technique
https://www.ncbi.nlm.nih.gov/pmc/articles/PMC3158461/

FYI FACIAL VEIN VS RETROBULBAR

- Teilmann et al. 2014.
  - B6 male, 5mo, n= 12/g
  - No anesthesia
  - RB 75ul ucapillary
  - FV lancet
- FV bled mice had elevated corticosterone
- FV bled had more wt loss than RB bled
- Both had tissue damage

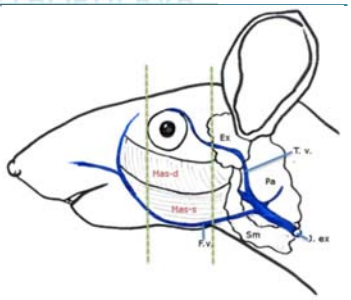

https://journals.plos.org/plosone/article?id=10.1371/journal.pone.0113225

34

FYI FACIAL VEIN VS RETROBULBAR

- Frohlich et al. 2018.
- Serial collections had worse outcomes than single collections.
- FV had worse outcomes than RB
  - FV ~33% mortality, clinical adverse events, tissue damage,

35

FYI BLOOD COLLECTION – TAIL

- Cross-section of rodent tail, showing vessels used for blood collection.
- Lindstrom et al 2015. Clin Lab Med. https://www.ncbi.nlm.nih.gov/pubmed/26297409
- Rats, Mice,
- Hamsters, Gerbils

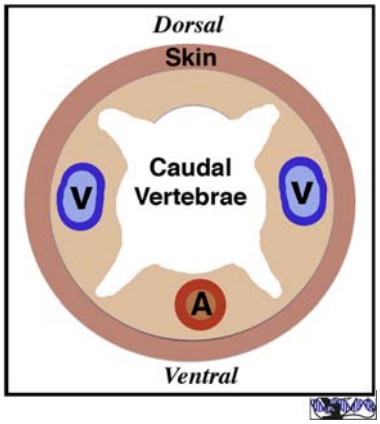

FYI TAIL OSSIFICATION (RE TAIL SNIPS)

- immature (IMV) or
- mature with end plates (MV) at 17do.
- Histo grades I-V, based on presence or absence of hypertrophic chondrocytes or bone in primary and secondary ossification centers
- B6 matured fastest.
- Collect minimal tail from mice younger than 17 d OR anestheyoze.
- Hankenson et al. 2008.

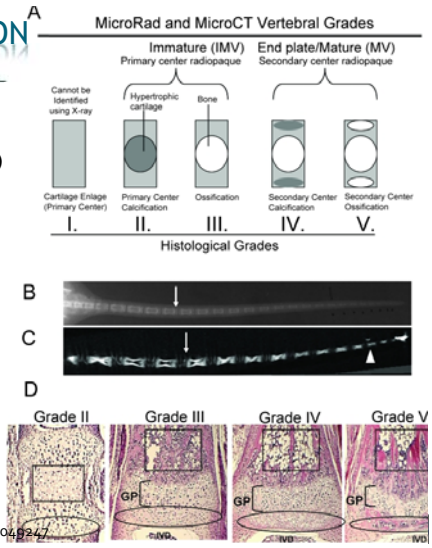

https://www.ncbi.nlm.nih.gov/pubmed/19049247

FYI CECUM LOCATION AND IP INJECTIONS

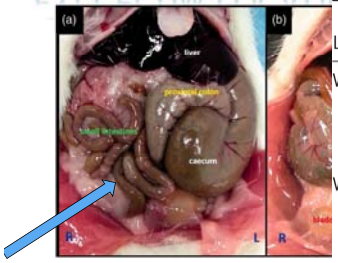

Where to inject ?

WHY?

- Lower right quadrant….

Murat et al Copyright © 2016 Laboratory Animals Limited
http://journals.sagepub.com/doi/full/10.1177/0023677216658916

Location	No.	% (per group)
Wistar albino rats (Female)		
Left	69	69
Right	25	25
Middle	6	6
Wistar albino rats (Male)		
Left	77	77
Right	15	15
Middle	8	8
BALB/c mice (Female)		
Left	43	86
Right	6	12
Middle	1	2
BALB/c mice (Male)		
Left	40	80
Right	8	16
Middle	2	4

CONCLUSION & FINAL EXAM

What methods are

- Best for your research needs ?
- Best for animal health and welfare ?
- APPROVED in your IACUC protocol, or by your ethical review committee?

Are you reporting the METHODS usefully, accurately?

39

JH Phenotyping Core Mouse Hematology (+References, Resources)
https://johnshopkins.corefacilities.org/service_center/show_external/3768

MOUSE HEMATOLOGY (CBC)

IDEXX ProCyte Dx® Hematology Analyzer; IDEXX Laboratories Inc; Westbook, ME

Mice: Strain, sex, age, immune status, disease conditions not specified

7 July 2016 to 21 August 2017 (N Forbes McBean); Exclusion criteria: Any Error Message

	RBC (M/µL)	HGB (g/dL)	HCT (%)	MCV (fL)	MCH (pg)	MCHC (g/dL)	RDW.SD (fL)	RET (K/µL)
Mean	**8.13**	**13.63**	**43.78**	**56.18**	**17.55**	**31.22**	**33.1**	**8.13**
Low	3.57	6.1	16.7	39	12.6	27	24.2	3.57
High	15.2	21.7	69.8	90.8	31	37.6	63.1	15.2
SD	2.13	2.01	6.93	10.74	3.57	1.51	5.09	2.13
n	1119	1119	1119	1119	1119	1119	1119	1119

	PLT (K/µL)	PDW (fL)	MPV (fL)	WBC (K/µL)	NEUT (K/µL)	LYMPH (K/µL)	MONO (K/µL)	EO (K/µL)	BASO (K/µL)
Mean	**675.09**	**8.97**	**7.34**	**7.52**	**2.79**	**4.12**	**0.45**	**0.11**	**0.05**
Low	59	5.7	5.2	1.06	0.03	0.12	0	0	0
High	2633	23.9	13.1	56.08	32.03	23.46	5.08	2.03	2.33
SD	369.3	2.29	1.65	4.81	3.25	2.87	0.59	0.14	0.18
n	1122	1122	1122	1122	1122	1122	1122	1122	1122

Concurrent relevant controls are critical to obtaining useful information from clinical pathology tests.

References, resources for mouse CBC (and clinical chemistry):

1. **Lies, Damn Lies, and Reference Intervals (or Hysterical Control Values for Clinical Pathology Data)**. Hall, R. 1997. *Toxicol Pathol* 25: 647
2. **MPD** Mouse Phenome database for mice by (J) strain, sex and age, with protocol detail https://phenome.jax.org/search/details/ssmeasures?searchterm=complete+blood+count+&ontavail=0
3. Khokhlova, O. N., et al. (2017). "Using Tiletamine-Zolazepam-Xylazine Anesthesia Compared to CO2-inhalation for Terminal Clinical Chemistry, Hematology, and Coagulation Analysis in Mice." J Pharmacol Toxicol Methods **84**: 11-19. **BALB/c (Pushchino); vena cava; EDTA, Mythic 18, veterinary software; serum, SAPPHIRE 400; Citrate, coagulometer CL 4**
4. Poitout-Belissent, F., et al. (2016). "Reducing blood volume requirements for clinical pathology testing in toxicologic studies-points to consider." Vet Clin Pathol **45**(4): 534-551.
5. Moorhead, K. A., et al. (2016). "Alterations due to **dilution and anticoagulant** effects in hematologic analysis of rodent blood samples on the **Sysmex XT-2000iV**." Vet Clin Pathol **45**(2): 215-224.
6. White, J. R., et al. (2016). "Evaluation of hematologic variables in newborn C57/BL6 mice up to day 35." Vet Clin Pathol **45**(1): 87-95.
   C57/BL6J [UI]; facial V, EDTA; 1:10 dilution; Sysmex XT-2000iV
7. Otto, G. P., et al. (2016). "Clinical Chemistry Reference Intervals for **C57BL/6J, C57BL/6N**, and **C3HeB/FeJ** Mice (Mus musculus)." J Am Assoc Lab Anim Sci **55**(4): 375-386.
   AU400, Olympus/ AU480, Beckman-Coulter, GMC IMPC
8. O'Connell, K. E., et al. (2015). "Practical murine hematopathology: a comparative review and implications for research." Comp Med **65**(2): 96-113.

9. Marx, J. O., et al. (2015). "The Effects of Acute Blood Loss for Diagnostic Bloodwork and Fluid Replacement in Clinically Ill Mice." Comp Med **65**(3): 202-216. **C57BL/6J; isoflurane; retroorbital; anticoag [NOS], Vet ABC + manual; 'Vitos' [Vitros Dry] 250 Chemistry Analyzer**
10. Kampfmann et al. 2012 Differences in hematologic variables in **rats** of the same strain but different origin. Vet Clin Pathol. 41(2):228-34. **Wistar; Isoflurane, sublingual V; EDTA; Sysmex XT-2000iV**
11. Fernandez, I., et al. (2010). "Clinical biochemistry parameters in **C57BL/6J** mice after blood collection from the **submandibular vein and retroorbital** plexus." JAALAS **49**(2): 202-206. **Selectra Junior Spinlab 10**
12. Mazzaccara, C., et al. (2008). "Age-Related Reference Intervals of the Main Biochemical and Hematological Parameters in **C57BL/6J, 129SV/EV and C3H/HeJ** Mouse Strains." PLoS One **3**(11): e3772. **Isoflurane, retroorbital; EDTA; ABX Pentra 60C; pooled blood [serum], dry chemistry Vitros 250**
13. Boehm, O., et al. (2007). "Clinical chemistry reference database for Wistar rats and C57/BL6 mice." Biological chemistry 388(5): 547-554. **Wistar [NOS], Thiopental, aorta or cardiac; C57/BL6 [NOS] , Pentobarbital, aorta or cardiac; Roche Cobas Mira S, Eppendorf EFOX 5053 Behring Nephelometer II**
14. Zhou, X. and G. K. Hansson (2004). "Effect of sex and age on serum biochemical reference ranges in C57BL/6J mice." Comp Med 54(2): 176-178. **[C57BL/6JBomTac]; CO2 cardiocentesis; Vitros dry chemistry.**
15. Doeing, et al. (2003). "Gender dimorphism in differential peripheral blood leukocyte counts in mice using cardiac, tail, foot, and saphenous vein puncture methods." BioMed Central Clinical Pathology 3(3): **C57BL/6 [CRL], methoxyflurane, heparin, manual, hemocytometer**
16. Forbes, N. and C. Brayton (2009). "P223 Practical Clinical Chemistry for Rodents: Dilution Effects." JAALAS **48**(5): 630. **VET ACE**
17. Forbes et al. (2015). "P39. Comparative Performance of Two Bench-Top Hematology Instruments for Macaques and Mice." JAALAS **54**(5): 568-668. **PROCYTE + HEMAVET**
18. Forbes, N. and C. Brayton (2008). "P186 Effects of Blood EDTA Saturation on Selected Mouse Hematology Variables." JAALAS **47**(5): 167. **HEMAVET**
19. Forbes, N., et al. (2006). "P86 Mouse Clinical Pathology: Controlling Variables That Influence Hematology Data." JAALAS **45**(4): 116. **HEMAVET**
20. Everds, N. (2006). Hematology of the Laboratory Mouse. . THE MOUSE IN BIOMEDICAL RESEARCH: Normative biology, husbandry, and models. J. Fox, S. W. Barthold, M. T. Davisson et al. Burlington, MA, US, Elsevier (Academic Press). **III:** 133-163. Ch 135.
21. Serfilippi, L. M., et al. (2003). "Serum Clinical Chemistry and Hematology Reference Values in Outbred Stocks of Albino Mice from Three Commonly Used Vendors and Two Inbred Strains of Albino Mice " Contemp Topics LAS **42**(3): 46-52. **Crl:CFW(SW) BR, Tac:(SW)fBR, HsdWin:CFW1, Crl:CD-1(ICR) BR, Tac:Icr:Ha(ICR)fBR, Hsd:ICR (CD-1), Crl:CF-1, Hsd:NSA(CF-1), FVB/NCrlBR, C57BL/6J-*Tyrc-2J/+*; CO2 cardiocentesis; EDTA, Bayer Technicon H1; SST, Hitachi 704**
22. Kile, et al. (2003). "Sex and strain-related differences in the peripheral blood cell values of inbred mouse strains." Mamm Genome **14**(1): 81-85. **Retro orbital, EDTA; ABBOT CELL DYN 3500R**

BOLD Font: Strain, collection site, anesthesia, anticoagulant, instrument

NOS = Not otherwise specified

Mouse Necropsy /Autopsy (ref Brayton, Mckerlie, Brown 2014[1]; Brayton 2001[2])

Necropsy (viewing the dead) refers to the *post mortem* examination of organs and tissues (autopsy = self + view). A necropsy technique should efficiently evaluate all tissues and lesions, and be reproducible and teachable. **Checklists** can help to ensure that all procedures are performed (e.g., photography, radiography, examination, also weighing/measuring of specified tissues and of lesions. Variations to the technique are justified by specific aims or requirements of a diagnostic procedure or research study. However a standardized systematic procedure, can improve comparisons within and between studies, even when initial examinations are months or years apart. [1 2 3 4 5 6]
Strategic use of pathology in research settings can include clinical and anatomic pathology to:

1. Assess disease problems, including decreased production, in breeding colonies;
2. Assess disease problems in research animals during studies;
3. Confirm and characterize phenotypes or other research endpoints;
4. Characterize and validate translational research models.

Equipment and Materials

1. **Protective Equipment (Including PPE personal protective equipment)**
   a. **Workstation**: A ventilated workstation such as a down-draft table or a fume hood to protect the prosector (person performing the necropsy) from fixative fumes or other hazardous materials.
   b. **PPE: Face /respiratory protection**: In addition to a downdraft table or appropriately ventilated hood, face masks or N95 type fitted respirator masks are used to protect sensitive individuals from mouse allergens.
   c. **PPE: Eye protection:** Glasses or goggles to protect eyes from splashes with fixative, other potentially hazardous materials, and allergens. Magnifying reading glasses may facilitate dissection and examination of small specimens.
   d. **PPE: Gloves**: Essential. When multiple animals will be examined, hand lotion and double gloving may work better than frequent glove changes. When the top gloves are damaged or soiled, replace only the top gloves, to minimize exposure of hands to drying or contaminating materials. Latex gloves are common. Vinyl gloves are useful for individuals with latex allergies.
   e. **PPE: Lab coats** or other apparel to protect skin and clothes from fixatives and contaminating materials.

2. **Cutting board:** An inexpensive, plastic cutting board is adequate for most purposes. It should be relatively easy to clean, and able to withstand frequent use. Some necropsy methods use pins and soft or porous cutting boards. Often these cannot be cleaned or decontaminated as easily as plastic, and can be quite expensive.
3. **Paper towels**: many tissues (e.g. skin and reproductive tract) can be laid flat on a paper towel, and will adhere to it to facilitate examination and ensure uniform fixation.
4. **Small metric ruler**: a ruler (or ruled label) should be included in photographs to facilitate subsequent measurements. A consistent location (e.g. lower right) that can be cropped out of the image, can be useful for publication. When a finding or organ is reported 'small' or 'large', it should be measured and/or weighed. Mass lesions and organs with three dimensions should have measurements recorded for 3 dimensions. A spot may be 2x3 mm, a mass may be 2x3x2 mm, or 2-3mm diam.
5. **Forceps**: blunt-ended, serrated, or toothed forceps seem to cause less damage to delicate mouse tissues. Fine-pointed forceps can create artifactual holes or tears. Smooth forceps can require extreme (and damaging) pressure to grip slippery tissue.
6. **Scissors**: fine, blunt-ended scissors seem to cause less damage. Sharp-tipped corneal scissors are common, but can make holes or tears, especially in inexperienced hands.
7. **Scalpel blades, single edge blades**: blades usually are not necessary for initial mouse dissections. Sharp, fresh blades are essential for trimming tissues for histology processing, to ensure a flat tissue surface in the paraffin block (See trimming section below). Inexpensive 15" inch single-edge blades may work as well or better than scalpel blades and handles.
8. **Syringes/ needles:** a 3-ml syringe with 20-22-gauge needle to infuse the lungs and GI tract with formalin. Smaller needles can be used, but may penetrate more deeply than expected, injecting material outside the lumen. Shorter needles (less than 1 inch or 2 cm long) are easier to handle.
9. **Fixative**: for routine immersion fixation for paraffin processing, dissected tissues should be submerged promptly in fixative, at 1:10 V:V proportions, i.e. ~1 ml of specimen per 10ml of fixative. Rocking or agitation of specimens in the container can improve exposure of tissue to fixative. 10% Neutral buffered formalin (10%NBF) is suitable for soft tissues in most situations, including immunohistochemistry. Other options are discussed elsewhere. [7 8 9 10 11]
10. **Decalcifying (demineralizing) Solutions:** boney tissues (e.g. head, spine, legs) can be decalcified quite easily for histology processing and evaluation. Some formic acid based solutions fix and demineralize simultaneously, so that mouse tissues are fixed and adequately demineralized for paraffin processing within 24 hours. Bouin's solution also fixes and demineralizes but does not penetrate very deeply. Specimen size, exposure time, or perfusion methods may need to be modified to optimize fixation and demineralization for different types of specimens. Once adequately demineralized, tissues should be processed promptly because overexposure to acids or chelators will compromise tissues for evaluation or other tests. Immunohistochemical techniques may or may not work on demineralized tissues.
11. **Tissue cassettes**: for paraffin processing. Cassettes can be compartmented, extra deep, extra large, or have extra fine grid for special needs.
12. **Specimen containers with labels**.
13. **Identification**: Redundant identification IN and ON containers is recommended.
    Labels in pencil on paper and on cassettes can be kept in fixative with tissues in container.
14. **Camera**: to document findings.

Necropsy Procedure
Ideally, evaluation begins immediately after death. If delay is unavoidable, refrigeration (not freezing) can slow decomposition. Dedicated and labelled refrigerators (i.e. not for food) should be used for research materials. Freezing is discouraged, because histopathology will be compromised. Following is a protocol for systematic external and internal examination, *en bloc* removal of viscera, followed by further dissection, examination, organ weights, and trimming for histology.

External examination

1. **Sex** (presence, absence or abnormalities of nipples, external genitalia);
2. **Weight** (body weight in grams, note if before or after bleeding, record the bleed site and volume of blood removed);
3. **Coat color** (albino, agouti, black, other); coat condition (alopecia, ulcers, note distribution, site and size of involved area);
4. **Eye color** (albino, pink, black; also note size and symmetry);
5. **Body condition**, (e.g., thin, adequate or good body condition, or obese, or semiquantitative scoring as in **Figure 1**)
6. **External lesions 'dysmorphology'** (e.g., domed head, microphthalmia, masses, open wounds, reduced or extra digits) should be described and measured.
7. **Palpate** for pups or other abdominal masses, or abdominal fluid. A sterile fluid sample can be obtained with a needle and syringe, for chemistry (BUN, protein), cytology, or microbiology. The consistency of any palpated masses should be described as soft or fluctuant, firm or hard. 'Hard' should be reserved for boney or mineralized masses.

Dissection and Examination
Begin by always orienting animals in the same direction (e.g. head up or head right) so that the side/site of lesions can be recalled accurately. Preference may be influenced by handedness of the prosector. Record lesions or unusual findings. Note color, consistency, size and or weight. Avoid fruit or vegetable descriptors. Specific steps in dissection follow:

1. **Remove the pelt:** this facilitates assessment of subcutaneous fat (minimal, adequate, ample, excessive), and exposes mammary tissue, subcutaneous lesions, and abdominal organs *in situ*:
   Pinch and separate OR incise the ventral abdominal skin (thinner skin in inguinal region), then exert gentle pressure cranially and caudally until the pelt is removed. Examine skin and animal.
   Aseptic collections of effusions or mass lesions can be done at this point.
2. **Remove the "chain" of salivary glands:** parotid, sublingual, submandibular salivary glands, with lymph nodes, extending from ear to ear under the chin. These usually fit, *in toto*, in one cassette (#4); Table 1, Fig 4.
3. **Open the abdomen,** xiphoid to pubis, and examine the contents *in situ*. Record abnormalities.
4. **Remove the sternum:** lift it by the xiphoid process and cut anteriorly through ribs and clavicles, to expose the thoracic cavity. Examine the contents, noting fluid or masses. Note absence or enlargement of the thymus. Save, fix thymus and sternum, laid flat on paper, or in **cassette 1**.
5. **Expose the trachea** by blunt dissection and use 3ml syringe/20-25g needle to **infuse lung** with fixative. The lungs should expand, and excess fixative will reflux up the trachea. Difficulty in infusion may be due to inflammatory or neoplastic processes. It is not necessary to clamp or tie the trachea. After infusion, it is important not to compress the lungs during subsequent dissection.
6. **Cut/separate the mandibular symphysis**, between incisors, with a scissors to separate mandibular rami and expose the tongue. Grasp the tongue with forceps or fingers, and gently retract caudally to remove the tongue, larynx, trachea, and esophagus from the head and neck. Continue retracting

to remove the heart and lungs, with aorta, esophagus and trachea, from the thorax. Use blunt dissection (fingers/scissors) to free these tissues. Examine the oral cavity.

7. **Examine the removed viscera (tongue to diaphragm).** The thyroid glands are immediately caudal to the larynx on either side of the trachea. They may be difficult to identify without magnification, but thyroid glands usually are included if 2-4 mm of trachea immediately caudal to the larynx is examined by histology. Lungs can be fixed in **cassette #2** (per Table 1) dorsum down.
8. **Split the pelvis** to facilitate complete removal of abdominal contents: push viscera laterally, insert closed scissors into the pelvic canal, then open scissors gently to separate the halves of the pelvis, usually along the pubic symphysis.
9. **Remove and examine the abdominal contents:** Grasp the diaphragm with the forceps, excise from the dorsal body wall, and retract gently to lift out all abdominal contents together. The adrenal glands and kidneys tend to remain, deep in the retroperitoneal space; use blunt dissection (fingers/scissors) to facilitate removal. You may nick the right kidney (with scissors) to facilitate identification later. Examine abdominal contents *ex situ*.
10. **Dissect off liver and spleen** for examination and weighing. A small liver lobe usually is attached to the lesser curvature of the stomach. Be certain to capture and include this lobe to ensure accurate liver weights. When manipulating the liver, lift it gently, or grasp parts that will not be submitted for histology (e.g. by diaphragm or smaller lobes). The median and left lateral lobes are the largest, and usually selected for histology, unless lesions are evident in other lobes, or if experimental protocol dictates otherwise. The gall bladder lies between the 2 'halves' of the median lobe. Lobes should be separated for fixation. The spleen should be dissected free and weighed intact, less fat and attached tissues. Usually it is fixed intact, then trimmed after fixation.
11. **Dissect off kidneys and adrenals** for examination and weighing. The right kidney and adrenal should be anterior to the left. Female adrenal glands normally are larger than male adrenal glands. Adrenals can be saved/ fixed in **cassette #3** (per Table 1).
12. **Dissect off reproductive tract.** Tissue caudal to the kidneys that is not bowel, is mostly reproductive tract and fat. Remove all of this. Lay it flat on a dry piece of paper and spread the tissues into anatomic orientation to facilitate examination, fixation and histology. The paper with attached tissue can be submerged in fixative. Or small tissues can be fixed in **cassette #8** (per Table1).
13. **Infuse and extend the gastrointestinal GI tract:** Infuse different segments with 0.5–1.0 ml of fixative via 3ml syringe/20-25g needle, usually <2ml fixative, aiming to fix and preserve the contents and mucosa *in situ*. This can be done earlier in the dissection procedure also. Extend the GI tract gently by grasping the stomach in one hand and the rectum (fecal balls) in the other, and separate gently from attachments. Then gently pull/dissect off the mesentery, lymph nodes, and pancreas. These pale, soft tissues may be difficult to distinguish grossly, but can be placed into a **cassette #5** (per Table 1) and fixed for histology examination.
14. **Submerge all tissues to be saved in at least 10x their volume of fixative**. Soft tissues and bones can be trimmed for histology processing as early as 20 hours after dissection.
15. **Bone** must be decalcified (demineralized) for routine FFPE (formalin fixed paraffin embedded) histology processing. Skin should be removed so that the solution can penetrate the bone. Limbs and spine can decalcify with muscle attached. Sternum may not require decalcification to permit evaluation of marrow. Morphology of fixed but not decalcified marrow usually is better than decalcified marrow. Formic acid based fixing/decalcifying solutions can demineralize most mouse tissue satisfactorily within 24 hours. Overexposure to the acid will digest the tissue and compromise staining and evaluation. With new or unfamiliar decal solutions, evaluate exposure periods to determine the best protocol. Similar to fixation, the ratio of tissue to solution should be approximately 1:10, the tissue covered completely by the solution, and gentle agitation or rocking may improve results.

16. **Photography** – Digital images become part of the data, and can be a key part of the publication. Camera phones or flat bed scanners can be useful for documentation. Short video clips of abnormal movements or behaviors can be useful. Images should be composed to facilitate comparisons within and between studies, permit measurements (include a ruler), and include identification for documentation. Orientation of the animal or specimens should be consistent, and should make sense anatomically. Images should illustrate the finding or comparison, and not horrify viewers. Identification or labeling is important for images, as it is for any other data.

Trimming fixed tissues for histology (Table 1)

Mouse tissues placed in cassettes during dissection can include lung, thyroid, trachea, adrenal glands, salivary glands, lymph nodes, pancreas, reproductive tract (if small). These may not require further trimming. Other tissues must be "trimmed" and placed into histology cassettes for processing.

CHECK NECROPSY Report for lesions to be trimmed. Trimming should be performed in a well-ventilated area or hood. Used fixative should be discarded as hazardous waste. After trimming, labeled cassettes should be submitted to the histology lab in clean fixative. Once fixed, tissues to be saved can be stored in clean fixative, sufficient to keep them moist, in sealable bags or other suitable containers.

Tissue cutting should be a single clean swipe of a sharp blade. NO sawing or squishing. Inexpensive 1.5in single-edge blades are suitable for most tissues. Blades should be replaced as soon as they do not cut well. Trimmed specimens should be <3mm thick to fit into standard cassettes without grid marks and "squish artifact." For brains or decalcified heads, longer blades, (2.25in Weck or similar) may improve sections. Decalcified tissue should cut easily. Crunchy tissue requires additional decalcification. Decalcified specimens should be rinsed in water, and cassettes can be kept for short periods in buffered saline until processing.

Cassette numbering should follow a system to facilitate retrieval of specific tissues from archived material. A graphite pencil remains the usual marker of choice because many inks are removed by alcohols in paraffin processing. **(Table 1)** summarizes a numbering system in a 10 slide protocol, with trimming recommendations for each tissue and cassette. Additional cassettes can be prepared to include lesions identified during dissection.

Histopathology

Table 2 summarizes common histology findings and lesions by slide number and tissue. Diagnostic criteria and terminology for gross findings and for histopathology findings should be standardized to facilitate comparisons within and between studies. Anatomy and pathology terminology should be consistent with widely used and published systems to facilitate communication and publication. [2 9 12] Figures 4 and 5 include referenced nomenclature for lymph nodes and mammary glands respectively.

Reporting and Archiving Data and Specimens

Data handling and reporting strategies vary with the resources and goals of the program or project. Paper copies of reports with a checklist for each system or tissue may be sufficient for some projects. Databases, servers and specialized hardware and software may be key to the success of large projects and multidisciplinary and collaborative efforts. Systems and strategies to handle and report pathology data and specimens should aim to preserve and protect data and specimens, to make them accessible for further evaluation, and to facilitate comparisons within and between studies. Pathology data frequently includes many large images that require significant data handling capabilities, and server space. Still photomicroscopy can exceed 5MB, scanned slides (virtual microscopy) can exceed 400MB. Archiving of specimens, including fluids, wet tissues, frozen tissues, paraffin blocks, glass slides, and virtual (digital) slides require planning and investment in preservation methods, identification, storage methods and capacity, and retrieval. [9]

Figure 1. Body Condition (BC) assessment from Ullman & Foltz 1999.[13]

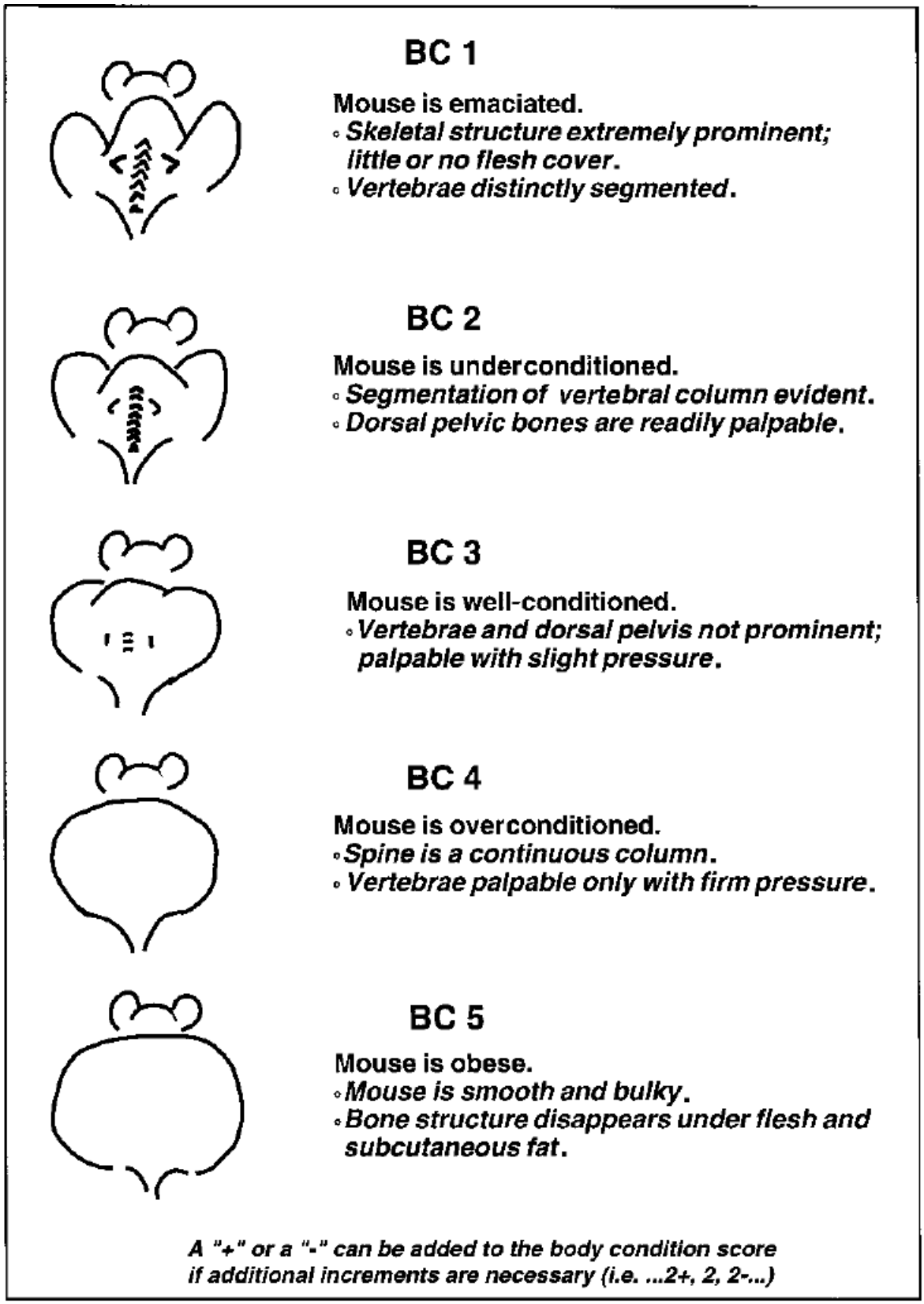

Fi

Table 1: Cassette (slide) numbering, tissues and trimming suggestions with [options, additional tissues]

Cassette #	Tissues	Table 1: Trimming suggestions
1	♥Heart	Heart: Hemisect (cut in half, longitudinally) to expose all chambers and valves. The right ventricle has a thinner wall than the left ventricle and may wrinkle slightly when pressed. For some purposes, multiple transverse (cross)-sections may be preferred.
	Thymus	Thymus: both lobes usually can be included intact; or section and place flat slide down. **Note absence if thymus is NOT found.**
	Tongue	Cross section or longitudinal section flat side down.
	Sternum	Place intact, deep or internal side down in cassette, to section to marrow easily; Trim off excess ribs to facilitate sectioning.
	[Diaphragm	Short strips can be sectioned on edge]
2	**Lung - entire**	Dorsal side down – can be put in cassette during initial dissection
	Trachea	Cross section at thyroid, or include intact for longitudinal section
	Esophagus	Include intact for longitudinal section
	Thyroid, parathyroid	Transect trachea at level of thyroid, or trim to evaluate lesions. [Special dissection (with dissecting microscope) and use of special cassettes are necessary for more specific evaluation of small tissues.]
	Aorta	Can be included attached to thoracic viscera, or dissected off and included separately.
	[Lymph nodes	Mediastinal nodes or small pieces of thymus may be attached but not seen at dissection]
3	Kidneys	Usually can include 2 sagittal sections of left kidney plus 2 cross sections of right kidney
	Adrenal glands	In cassette already. Small adrenals may require special cassettes (with smaller holes), sponges, or tea bags; consult histo lab regarding their preferences for tiny bits.
	[Lymph nodes	Frequently included with pararenal fat and adrenals. See Fig 4.]
4	Salivary glands with lymph nodes	In cassette: paired parotid, sublingual and submandibular salivary glands (with attached lymph nodes - Fig 4.). These were removed *in toto* by dissecting them off underlying tissue, from one ear canal to the other. Measure /record abnormalities (e.g. large Lnodes, tumors).
	Exorbital lacrimal glands	Sometimes included when salivary glands are dissected off *in toto*
	Auditory sebaceous gl.	Sometimes included when salivary glands are dissected off *in toto.* More likely to be found in head section (10).
	Lymph nodes	Usually included when salivary glands are dissected off *in toto.* See Fig 4.
	Mammary gl.	Often included in female mice when salivary glands are dissected off. See Fig 4,5.
5	Pancreas	In cassette: During dissection, pancreas, fat, mesentery and lymph nodes, were stripped from the GI tract to include in this cassette. These tissues can be difficult to distinguish grossly but are readily identified microscopically.
	Lymph nodes, fat, vasculature	Usually included in this section – See Fig 4
6	Stomach	Section to include forestomach and glandular stomach
	Small intestine Cecum, colon	Include cross sections or segments according to your needs, or histology lab preference s
[6 a, b, c	Swiss roll Open]	Immediately after euthanasia, the intestine is opened (incised longitudinally), examined, fixed, and rolled into 1 or 2 deep cassettes
[6 a, b, c	Swiss roll Closed]	Alternatively, at dissection, after infusion with fixative, **before fixation,** intact (closed) small intestine can be rolled into 1 cassette, Large intestine rolled into 2nd cassette; cecum and stomach sectioned into 3rd cassette. (fixed intestines do not roll well into cassettes)

7	Liver	1 Section through left lateral lobe, hilus to periphery; 1 Section through median lobe to include gall bladder; include lesions in any lobes. Measure /record abnormalities.
	Gall bladder	Should be included with median lobe; can be sectioned separately if enlarged.
	Spleen	Usually spleen can be hemisected along its long axis, and one or both halves evaluated. (Some projects protocols request cross sections). A small spleen may be included intact.
8 Female	Uterus Ovaries Vagina	Reproductive tract can be fixed flat, intact on paper. A small reproductive tract can be included intact in the cassette before or after fixation. For larger tracts or for lesions, cross sections or segments of different regions should be included in the cassette. Measure /record abnormalities.
	Urinary bladder	A small bladder is included with entire tract in the cassette; or section/separate at trimming.
8 Male	Testes Epididymis Seminal vesicle + coagulating glands	Reproductive tract can be fixed flat, intact on paper. A small reproductive tract can be included intact in the cassette before or after fixation. For larger tracts or for lesions, cross sections or segments of different regions should be included in the cassette. Large seminal vesicles are common in older males; 1 or 2 cross sections can be assessed. Measure /record abnormalities.
	Prostate	Parts are included in sections when the entire tract is included in the cassette; [Alternatively cross section at neck of baldder; OR lobes can can be dissected and fixed separately.]
	Urinary bladder	A small bladder is included with entire tract in the cassette; or section/separate at trimming.
9	Skin	Cut ~3mm diameter ribbons of flat, fixed skin, parallel to hair growth and to long axis of mouse, including facial skin, clitoral or preputial glands. BE SURE TO INCLUDE any abnormalities/lesions noted in the report.
	Mammary glands	Usually included with female skin sections; or mammary pads can be harvested and evaluated specifically.
	Preputial or clitoral glands	Sebaceous glands (2 lobes) in inguinal subcutis, near genital openings.
	[+/- Decalcified leg]	May be included in this cassette (consult histo lab, do not crowd cassette). Trim tissue from medial aspect so that femur is seen on the flat (cut) surface; remove excess and poorly decalcified tissue e.g. feet). USE separate cassette/slide for specific assessments or lesions.
10	Decalcified Head In cassette: Front Down - Front Down - Back Down - Back Down - Back Down -	Use consistent orientation and anatomic landmarks Fig 2,3, to achieve comparable sections between cases. External ear canal openings and eyes are useful landmarks. Holding the nose in one hand, using clean, single strokes, make 4 or 5 sections, from caudal to rostral, that usually fit in one cassette. 1) Cut just caudal to ear canal for a section that includes cerebellum, medulla 2) Cut just rostral to ear canal for section to include middle ear, internal ear, or both; pituitary, thalamus, hippocampus. 3) Cut just caudal to eyes for section with cerebrum, usually hippocampus, thalamus 4) Cut just rostral to eyes for section with eyes, Harderian glands, oral cavity, molars. 5) Nose section. In long nosed mice, the nose may need additional trimming; Large heads may require 2 cassettes OR trim off mandible pieces for 1 cassette.
[11	Decalcified spine	Cervicothoracic and lumbosacral spine segments (with muscle, vertebrae, spinal cord) usually can be accommodated in a total of 2 cassettes. 3 Cross-sections: 1) rostral spine; 2) at last rib (thoracolumbar junction); 3) sacral area; 2 Longitudinal sections: 1) cervicothoracic, 2) lumbar, are obtained by sectioning tissue cleanly from one side of segment to the level of vertebral bone, to provide a flat surface on the paraffin block, for sectioning into deeper tissues including spinal canal and cord
12 etc	Lesions:	CHECK NECROPSY REPORT TO ENSURE TRIMMING OF ANY RECORDED FINDINGS: Trim lesions to include adjacent normal issue for perspective and context, to reflect gross measurements and photographs, and correlate to gross findings.

Figure 2: Mouse head, anatomic landmarks, and sectioning decalcified specimens

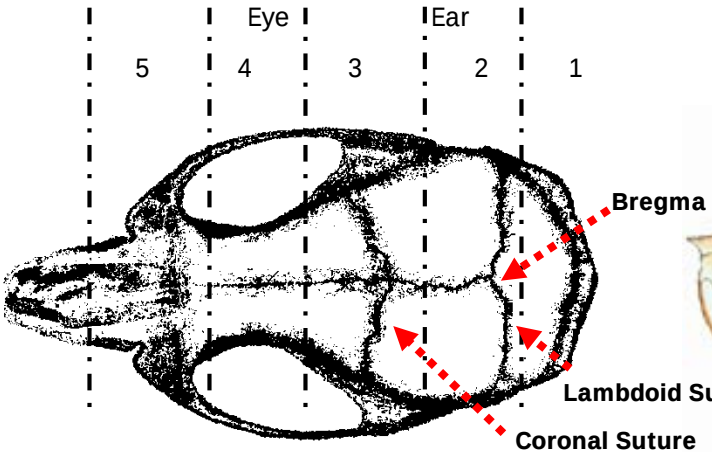

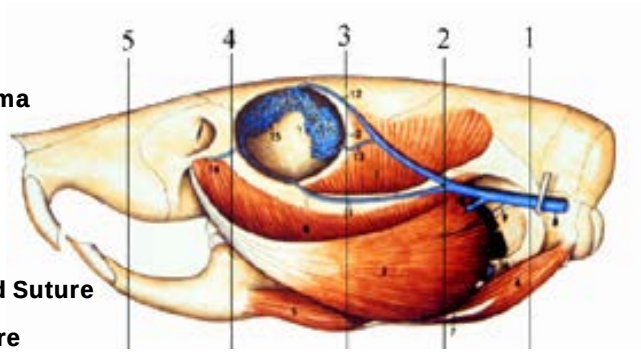

Adapted from Paxinos & Franklin 2001 [14]

Adapted from Popesko et al. 1992 [15].

Figure 3. Decalcified Mouse head - 5 transverse histology sections. Numbered in order of cut, caudal to rostral (Large heads may require an additional cassette, or additional trimming):

1. Cerebellum (section placed in cassette front/rostral/anterior side down);
2. Ears/hippocampus/Pituitary (section placed in cassette front/rostral/anterior side down);
3. Cerebrum (section placed in cassette back/caudal/posterior side down);
4. Eyes, oral cavity (section placed in cassette back/caudal/posterior side down);
5. Nose, vomeronasal, incisors etc (section placed in cassette back/caudal/posterior side down); long noses may require additional trimming to fit in cassette.

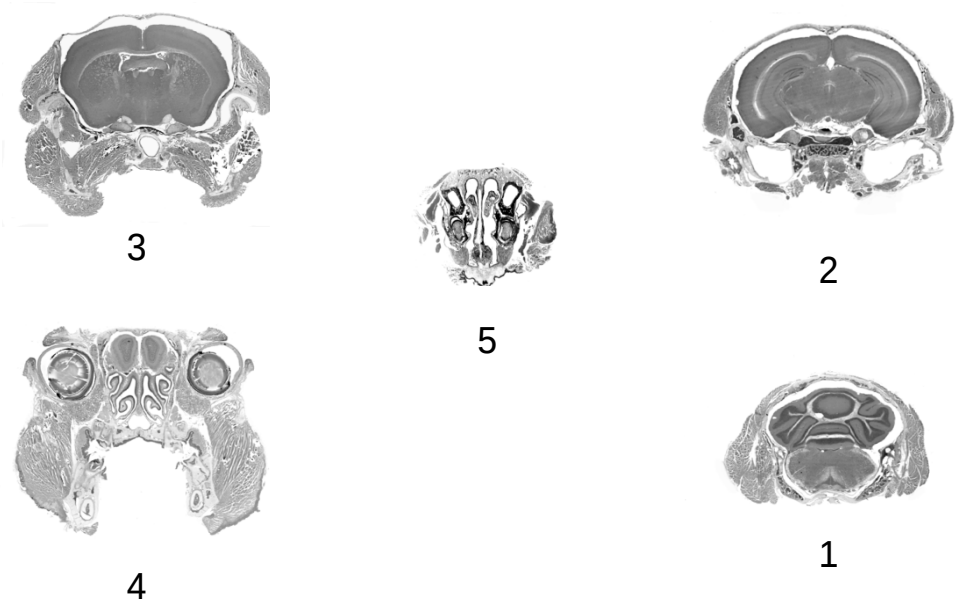

Figure 4. Mouse Lymph Nodes (adapted from Van den Broeck, et al. (2006).[16]

#	English name	Nomina Veterinaria
1	**Mandibular lymph node**	**Ln. mandibularis**
2	**Accessory mandibular ln.**	**Ln. mandibularis accessorius**
3	**Superficial parotid ln.**	**Ln. parotideus superficialis**
4	**Cranial deep cervical ln.**	**Ln. cervicalis profundus cranialis**
5	Proper axillary ln.	Ln. axillaris proprius
6	Accessory axillary ln.	Ln. axillaris accessorius
7	Subiliac ln.	Ln. subiliacus
8	Sciatic ln.	Ln. ischiadicus
9	Popliteal ln.	Ln. popliteus
10	Cranial mediastinal lnn.	Lnn. mediastinales craniales
11	Tracheobronchal ln.	Ln. tracheobronchalis
12	Caudal mediastinal ln.	Ln. mediastinalis caudalis
13	**Gastric ln.**	**Ln. gastricus**
14	**Pancreaticoduodenal ln.**	**Ln. pancreaticoduodenalis**
15	**Jejunal lnn.**	**Lnn. jejunales**
16	**Colic ln.**	**Ln. colicus**
17	Caudal mesenteric ln.	Ln. mesentericus caudalis
18	Renal ln.	Ln. renalis
19	Lumbar aortic ln.	Ln. lumbalis aorticus
20	Lateral iliac ln.	Ln. iliacus lateralis
21	Medial iliac ln.	Ln. iliacus medialis
22	External iliac ln.	Ln. iliacus externus

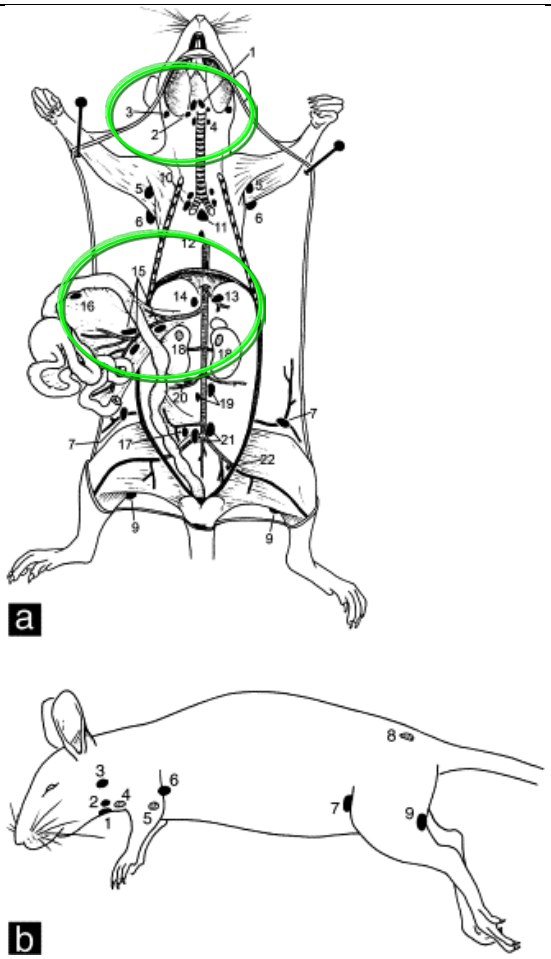

Figure 5. Mouse Mammary glands (adapted from Dunn 1951[17] &/or Cloudman 1936,[18] 1941[19])

A (lateral view)
1. Mammary Gland-Left Cervical
2. Mammary Gland-Left Thoracic
3. Mammary Gland-Left Thoracic
4. Mammary Gland-Left Abdominal

B (ventral view)
1. Mammary Gland-Left Cervical
2. Mammary Gland-Left Thoracic
3. Mammary Gland-Left Thoracic
4. Mammary Gland-Left Abdominal
5. Mammary Gland-Left Inguinal
6. Mammary Gland-Right Cervical
7. Mammary Gland-Right Thoracic
8. Mammary Gland-Right Thoracic
9. Mammary Gland-right Abdominal
10. Mammary Gland-Right Inguinal

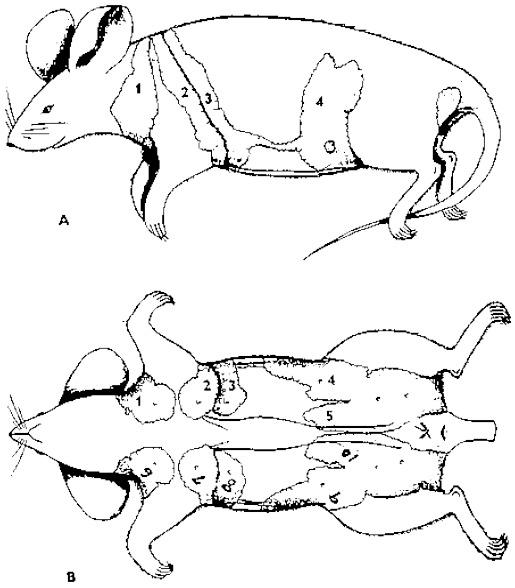

See also Nomina anatomica veterinaria, 6th ed – 2017 http://www.wava-amav.org/wava-documents.html

Table 2: Histopathology evaluation, by slide number and tissue. [20 21]

Slide #	Tissues	Table 2: Common features and lesions to look for on histology:
1	**♥Heart**	Enlarged chambers, thickened walls, myofiber degeneration loss or hypertrophy, Inflammation, fibrosis, mineralization, thrombi, amyloid.
	Thymus	Two lobes? Distinct medulla and cortex? apoptosis or necrosis? Large: neoplasia? Hyperplasia or inflammation; Small: lymphoid depletion or hypoplasia (as in nude or scid mice) ; Cysts, ectopic thyroid or parathyroid.
	Tongue	Inflammation, mineralization, myofiber changes.
	Diaphragm	Myofiber changes as in muscular dystrophy or other myopathy
	Sternum	Marrow: Cellularity? Trilineage hematopoiesis; Myeloid: erythroid M:E ratio (approx.); Neoplasia; fibroosseous lesion/ proliferation. Muscle – myofiber degeneration regeneration, atrophy, fibrosis, fat, mineral.
2	**Lung - entire**	Inflammation (pneumonia), infection, neoplasia;
	Trachea	Inflammation primarily;
	Esophagus	Inflammation primarily;
	Thyroid, parathyroid	Hyperplasia, neoplasia, ectopic thymus, inflammation, amyloid;
	Aorta	Atheromatous lesions, aneurysms, inflammation or mineralization in susceptible mice.
3	Kidneys – right/cross, left /long	Hydronephrosis, nephropathy, amyloid (glomerular, interstitial), inflammation, mineralization
	Adrenal glands	Inflammation, neoplasia, cortical nodules, X zone vacuolation in females, subcapsular cell hyperplasia and pigment (ceroid) laden cells in old mice
	Lymph nodes	Inflammation, hyperplasia (reactive), hypoplasia, atrophy or depletion, neoplasia.
4	Submandibular glands	Larger in male with more acidophilic ductules, Inflammation, neoplasia, degeneration/atrophy, cysts –ductal?
	Sublingual salivary glands	Inflammation, neoplasia, degeneration/atrophy.
	Parotid salivary glands	Inflammation, neoplasia, degeneration/atrophy, amyloid.
	Exorbital lacrimal glands	Inflammation, neoplasia, degeneration/atrophy.
	[Auditory sebaceous glands	Inflammation, neoplasia – likelier to see this on head slide (10).
	Lymph nodes	Lymphadenomegaly due to inflammation, hyperplasia, neoplasia; Small lymph nodes e.g. due to atrophy or depletion, or hypoplasia (as in nude or scid mice) .
	Mammary glands	In females: Inflammation, hyperplasia, galactorrhea (milk production), neoplasia.
5	Pancreas exocrine	Adequate and uniform zymogen distribution, zymogen depletion, exocrine atrophy or loss, neoplasia (rare unless GM).
	Pancreas endocrine	Islet inflammation (insulitis), degeneration (as in some diabetes models), hyperplasia (especially in fat mice), neoplasia (rare).
	Lymph nodes	As above
	Mesentery	Vasculature: Arteritis, periarteritis.
	Fat white and or brown	Adequate; atrophy small cells; hypertrophy large cells (as in fat mice); Fat necrosis, mineralization, inflammation; Inflammation with or without bacteria, associated with injection?

Slide #	Tissues	Table 2: Common features and lesions to look for on histology:
6	Forestomach	Scant ingesta ? hyperkeratosis ? Inflammation, erosion, ulceration, hyperplasia, neoplasia; Expected (friendly) bacteria Lactobacillus-like? (Enterococcus like); Trimorphic yeasts? Cw candidiasis? Blood/pigment in lumen?
	Glandular stomach	Inflammation, erosion, ulceration, hyperplasia, neoplasia; Superficial yeasts (*Kazachstania* sp)? *Cryptosporidium muris* (in glands)?
	CONTENT	Adequate ingesta in stomach? Expected (scant) micro flora ? blood or blood pigment?
	Duodenum	Inflammation, erosion, ulceration, hyperplasia, neoplasia; Blood/pigment in lumen? *Giardia muris, Spironucleus muris*; Blood/pigment in lumen?
	Jejunum	Inflammation, erosion, ulceration, hyperplasia, neoplasia Cestodes, coccidia; Blood/pigment in lumen?
	Ileum,	Inflammation, erosion, ulceration, hyperplasia, neoplasia, **amyloid**: *Cryptosporidium parvum*; (SFB segmented filamentous bacteria ~ Normal flora)
	Cecum	Inflammation, erosion, ulceration, hyperplasia, neoplasia; Nematodes: pinworms v other?; flagellates, entamoebae.
	Colon	Inflammation, erosion, ulceration, hyperplasia, neoplasia; Nematodes: pinworms v other?; flagellates, entamoebae.
	Rectum	Prolapse? Inflammation, erosion, ulceration, hyperplasia, neoplasia; Nematode larvae in crypts?
	CONTENT	Adequate ingesta /digesta? Expected micro flora ? blood pigment?
7	Liver (L Lateral+ Median Lobe/)	Inflammation, neoplasia, hepatocyte vacuolation (lipid, glycogen, etc.) degeneration, pigment (usually hemosiderin or bile), hepatocyte degeneration or necrosis, with syncytia or inclusion bodies, hepatocyte hypertrophy, anisocytosis, anisokaryosis, biliary hyperplasia, cholestasis.
	Gall bladder	Inflammation, erosion, ulceration, hyperplasia, neoplasia; Hyalinosis or crystals in mucosa.
	Spleen	Splenomegaly (by weight): Inflammation, hyperplasia, neoplasia, pigment hemosiderin or melanin in pigmented strains, amyloid; Small spleen (by weight): depletion or hypoplasia as in nude or scid.
8 Female	Uterus	Inflammation (pyometra or metritis), hyperplasia – cystic?, neoplasia; Embryos, Implantation sites, atrophy: pigment, mineralization.
	Ovaries	Normally developing follicles, corpora lutes, atretic follicles, oviduct; Neoplasia, cysts, atrophy, pigment, amyloid.
	Vagina	Inflammation, erosion, ulceration, hyperplasia, neoplasia; Hyperkeratosis, mucification; granulocytes compatible with cycle ?
	Urinary bladder	Inflammation, erosion, ulceration, neoplasia.
8 Male	Testes	Active spermatogenesis? reduced spermatogenesis? degeneration or loss of seminiferous epithelium; neoplasia, Interstitial cell hyperplasia or neoplasia; Inflammation or sperm granulomas.
	Epididymis	Mature sperm? Degenerate cells or giant cells, inflammation;
	Seminal vesicle + coagulating glands	Distention, inflammation, hyperplasia, neoplasia;
	Prostate	Inflammation, hyperplasia, neoplasia;
	Urinary bladder	Inflammation, erosion, ulceration, neoplasia, submucosal lymphoid infiltrates or nodules.

9	Skin	Inflammation, erosion, ulceration, bacteria, hyperplasia, neoplasia; Acanthosis, hyperkeratosis, and bacteria compatible with *C bovis*?
	Subcutis	Adequate fat? Inflammation, neoplasia.
	Mammary glands	Inflammation, hyperplasia, galactorrhea, neoplasia.
	Preputial or clitoral glands	Inflammation, abscesses, bacteria, hyperplasia, neoplasia.
	+/- leg decalcified	Muscle – myofiber degeneration regeneration, atrophy, fibrosis, fat, mineral. Marrow: Cellularity? Trilineage hematopoiesis; Myeloid: erythroid M:E ratio (approx.); Neoplasia; fibroosseous lesion/ proliferation.
10	Decal Head	
	Brain	Dilated ventricles (collapsed cortex?); corpus callosum? Inflammation; neuron necrosis/pyknosis; neuropil loss/rarefaction; neoplasia; Artifacts Hemorrhage (cervical dislocation?); white matter vacuolation?
	Pituitary	Hyperplasia, neoplasia, cysts;
	Ears	Inflammation, bacteria, neoplasia;
	Eyes	Retina, retinal degeneration, cataracts, cornea inflammation (keratitis), mineralization, neoplasia;
	Harderian glands	Inflammation, neoplasia (esp adenomas), atrophy, pigment (porphyrin);
	Bone, marrow	As above.
	TM joint	Arthritis, osteoarthritis, degenerative joint disease?
	Oral cavity	Inflammation, neoplasia;
	Incisor teeth	Dysplasia, inflammation, fracture; Ameloblast/odontoblast necrosis/loss;
	Molar teeth	Periodontal hairs and inflammation, alveolar bone loss, hypercementosis.
11	Spine decal	Neoplasia, hematopoietic involving marrow and adjacent tissue; Osteosarcoma or other tumors?
12 etc	Lesions:	

Online Resources for Pathology, Terminology and Diagnostic criteria

1. Frith CH and Ward JM. A Color Atlas of Neoplastic and Non Neoplastic Lesions in Aging Mice. Elsevier, London, 1988. (Print on demand available through the Davis-Thompson Foundation at http://www.cldavis.org/ . Ebook available at http://www.informatics.jax.org/frithbook/ [22]
2. ICVHN International Committee on Veterinary Histological Nomenclature. 2017. *Nomina Histologica Veterinaria*, 1st ed. Available online at http://www.wava-amav.org/wava-documents.html
3. NTP National Toxicology Program. Non Neoplastic Lesion Atlas https://ntp.niehs.nih.gov/nnl/
4. NORECOPA Mouse Necropsy https://norecopa.no/norina/guide-to-the-necropsy-of-the-mouse PREPARE Guidelines on Necropsy https://norecopa.no/prepare/15-necropsy with links to JOVE videos etc resources.
5. Mouse Tumor Biology (MTB) Database http://tumor.informatics.jax.org/mtbwi/index.do
6. Pathbase: European mutant mouse pathology database http://www.pathbase.net/
7. RENI Tissue trimming guide http://reni.item.fraunhofer.de/reni/trimming/index.php
8. Visible Mouse at UCDavis http://tvmouse.ucdavis.edu/

References in order of appearance

1. Brayton C, McKerlie C, Brown S. Analysis of Phenotype. In: Pinkert CA, ed. *Transgenic Animal Technology, A Laboratory Handbook.* 3 ed.: Elsevier; 2014:431-488.
2. Brayton C, Justice M, Montgomery CA. Evaluating mutant mice: anatomic pathology. *Vet Pathol.* 2001;38(1):1-19.
3. Brayton CB, Treuting PM. Phenotyping. In: A Mouse R, and Human Atlas, ed. *Comparative Anatomy and Histology: A Mouse, Rat, and Human Atlas.* 2 ed.: Elsevier; Academic Press; 2017:9-21.
4. Cardiff RD, Miller CH, Munn RJ. Analysis of mouse model pathology: a primer for studying the anatomic pathology of genetically engineered mice. *Cold Spring Harb Protoc.* 2014;2014(6):561-580.
5. Cardiff RD, Miller CH, Munn RJ, Galvez JJ. Structured reporting in anatomic pathology for coclinical trials: the caELMIR model. *Cold Spring Harb Protoc.* 2014;2014(1):32-43.
6. Scudamore CL, Soilleux EJ, Karp NA, et al. Recommendations for minimum information for publication of experimental pathology data: MINPEPA guidelines. *J Pathol.* 2016;238(2):359-367.
7. Cardiff RD, Hubbard NE, Engelberg JA, et al. Quantitation of fixative-induced morphologic and antigenic variation in mouse and human breast cancers. *Lab Invest.* 2013;93(4):480-497.
8. Mori H, Soonsawad P, Schuetter L, et al. Introduction of Zinc-salt Fixation for Effective Detection of Immune Cell-related Markers by Immunohistochemistry. *Toxicol Pathol.* 2015;43(6):883-889.
9. Brayton C, Treuting P. Phenotyping. In: Treuting P, Dintzis S, eds. *Comparative Anatomy and Histology: A Mouse and Human Atlas* London: Elsevier (Academic Press); 2012:361-381.
10. Fiette L, Slaoui M. Necropsy and sampling procedures in rodents. *Methods Mol Biol.* 2011;691:39-67.
11. Slaoui M, Fiette L. Histopathology procedures: from tissue sampling to histopathological evaluation. *Methods Mol Biol.* 2011;691:69-82.
12. Elmore SA, Cardiff R, Cesta MF, et al. A Review of Current Standards and the Evolution of Histopathology Nomenclature for Laboratory Animals. *ILAR J.* 2018.
13. Ullman-Cullere MH, Foltz CJ. Body condition scoring: a rapid and accurate method for assessing health status in mice. *Lab Anim Sci.* 1999;49(3):319-323.
14. G. P, Franklin KBJ. *The mouse brain in stereotaxic coordinates. 2nd Edition.* New York: Academic Press; 2001.
15. Popesko V, V. R, Horák J. *A Colour Atlas of the Anatomy of Small Laboratory Animals. Vol. II. Rat, Mouse, Hamster.* . London Wolfe Publishing Ltd; 1992.
16. Van den Broeck W, Derore A, Simoens P. Anatomy and nomenclature of murine lymph nodes: Descriptive study and nomenclatory standardization in BALB/cAnNCrl mice. *Journal of Immunological Methods.* 2006;312(1-2):12-19.
17. Dunn TB. Morphology of mammary tumors in mice with and without the agent. *Acta Unio Int Contra Cancrum.* 1951;7(2):234-237.
18. Cloudman AM. Gross and microscopic diagnoses in mouse tumors at the site of mammary glands. *American Journal of Cancer.* 1936(27):510-512.
19. Cloudman AM. Spontaneous neoplasms in mice. In: Snell GD, ed. *BIOLOGY OF THE LABORATORY MOUSE* New York, NY: Dover 1956 (McGraw Hill 1941); 1941:168-233.
20. Brayton C. Spontaneous Diseases in Commonly Used Mouse Strains In: Fox JG, Barthold SW, Davisson M, Newcomer CN, Quimby F, Smith A, eds. *The Mouse in Biomedical Research.* Vol II. Diseases. 2nd ed. New York: Elsevier (Academic Press); 2006:623-717.
21. Spontaneous diseases in commonly used mouse strains and stocks. MPD:Brayton1. The Jackson Laboratory; 2014. https://phenome.jax.org/projects/Brayton1.
22. Frith CH, Ward JM. *A Color Atlas of Neoplastic and Non Neoplastic Lesions in Aging Mice.* Elsevier (Print on demand available through the Charles Louis Davis Foundation at http://www.cldavis.org/. Electronic version available online at http://www.informatics.jax.org/frithbook/); 1988.

JHU MCP PHENOTYPING CORE

MOUSE NECROPSY



Standard Protocol: 10 slides > 40 tissues

Forbes, Brayton 2019 rev

Download from manual at http://mcp.bs.jhmi.edu/phenotyping-core

Reference: https://www.elsevier.com/books/transgenic-animal-technology/pinkert/978-0-12-410490-7

Brayton, Mckerlie, Brown. 2014. CH 16. Analysis of Phenotype. Transgenic Animal Technology, A Laboratory Handbook. 3rd ed. 431-488. Elsevier.

1

BAD SUBMISSION? GOOD SUBMISSION?

☹
Not perfused
Not enough fixative /formalin
Missing weights.... Missing tissues ....
Missing/lost labels ...

A 10 SLIDE MOUSE PROTOCOL

- Perfusion & Dissections by Nadine Forbes;
- Slides by Bonnie Gambicher;
- Slide scanning courtesy Flagship Biosciences;
- REF. Brayton, Mckerlie, Brown. 2014.

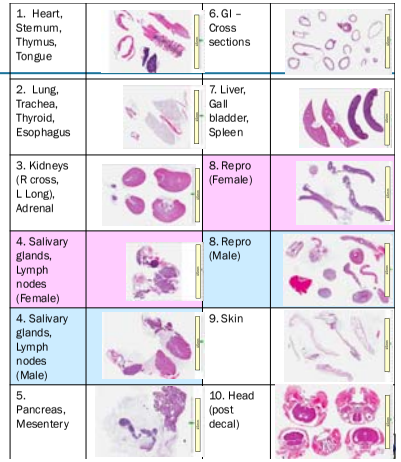

PROCEDURE SUMMARY

I. **Materials**
II. **Plan: Records, Cassette Numbering, etc**
III. **External Examination,**
- **CONFIRM IDENTIFICATION**

IV. **Dissection, Collection**
V. **Decalcification**
VI. **Trimming**

Download from manual at http://mcp.bs.jhmi.edu/phenotyping-core

4

I. MATERIALS

1. Prosector (recorder, photographer are nice too)
2. Relevant records (history) & report forms
   - IANR = Individual Animal Necropsy Record/Report Project specific, check list for collections, record abnormalities
3. Ventilated work station
4. PPE (Chemical hazards; allergens; biohazards)
   - Eye protection
   - Gloves
   - Lab coat or other protective uniform
5. Measuring tools → QUANTITATIVE data
   - Small metric ruler
   - weighing scale (0.001g)
6. Fixative and decalcifying solutions

5

I. MATERIALS (CONTINUED)

7. Cutting Board
8. Paper Towels
9. Instruments
10. Scissors (fine/blunt & student grade for skin, paper)
11. Blades
12. Syringes and needles
13. Decalcifying solution
14. Specimen containers
15. Pencils/markers
16. Labeled cassettes (next section)

6

I. MATERIALS (CONTINUED)

Syringes

- **1ml syringe** w/ 22-25 G needle
  - For cardiocentesis
  - Remove needle before ejecting blood into tube(s)
- **3ml syringe** w/ 20-25 G needle
  - For infusion of lung and GI tract w/ fixative

7

I. MATERIALS (CONTINUED)

Fixatives:

- **NBF** = 10% neutral buffered **Formalin**
  - Formalin (37-40% formaldehyde) 100ml
  - Sodium phosphate, monobasic, monohydrate 4.0 g
  - Sodium phosphate, dibasic, anhydrous 6.5 g
  - **dH2O** **to 1 liter**
  - pH
- **Other options**
  - Bouin's, Fekete's, Telly's etc acid alcohol
  - PFA – paraformaldehyde – for ISH etc

8

I. MATERIALS (CONTINUED

Decalcifying Solutions (Decal)

- Nitrical ® – **Not** a fixative – strong, fast
  - Nitric acid, water
- Decal Stat ® – **Not** a fixative, strong < 1hr!
  - HCL, EDTA, water
- Decal ® – **Not** a fixative, not as fast - overnight.
  - HCL, EDTA, water
- Immunocal ® – **Not** a fixative, gentler? overnight
  - Formic acid, water – better for immuno-histochemistry?
- **Formical-4 ® – fixative** /decalcifier, gentler ~ 24hr.
  - Formic acid, EDTA, Formaldehyde, water

9

II. PLAN: RECORD REPORT FORMS

1. Report form for collecting storing data usefully.
   a) e.g. IANR = Individual animal necropsy report
   b) Consider GLP etc requirements
2. Standard/general format or customized for the project
   a) Checklist format ? to ensure examination collection weighing measuring as necessary, facilitate transcription to electronic formats
   b) Text areas
   c) Examples in the lab manual.
   d) Electronic formats ?
3. Plan to save /archive these – scan + hardcopy files?

10

II. PLAN: CASSETTE NUMBERING (JH)

1. Heart, thymus, tongue, sternum
2. Lungs, trachea, thyroid/parathyroid, esophagus
3. Kidneys, adrenals
4. Salivary glands, cervical lymph nodes
5. Pancreas, mesentery, mesenteric lymph nodes
6. GI tract
7. Liver, spleen
8. Repro. tract, urinary bladder, (+/- rectum)
9. Skin, clitoral/preputial gland (+/- Decal leg)
10. Head – decalcified

➢ *Other systems may suit your projects better.*

11

II. CASSETTE OPTIONS

- Size, depth, compartments, hole size
- Disposable vs stainless tops;
- Consider storage archiving labelling options as well..

www.fishersci.ca

12 http://www.leicabiosystems.com/

III. EXTERNAL EXAMINATION

1. **Check records, identification** – *correct animal?*
2. **Weigh.**
3. **Observe - measure, quantify whenever possible.**
   - Identifying tags, marks, ear punches, amputations;
   - Color of coat and eyes;
   - Wounds, lesions, masses, alopecia, etc;
   - Presence/absence of vibrissae, nipples, etc.
4. **Palpate - measure, quantify whenever possible**
   - **Body condition**;
   - Abdominal mass (soft, fluctuant, firm, hard);
   - Abdominal fluid (obtain sterile sample);
   - Skin/Subcutaneous masses.

13

BODY CONDITION

➢ From Ullman Cullere & Foltz 1999

BC 1
Mouse is emaciated.
- Skeletal structure extremely prominent; little or no flesh cover.
- Vertebrae distinctly segmented.

BC 2
Mouse is underconditioned.
- Segmentation of vertebral column evident.
- Dorsal pelvic bones are readily palpable.

BC 3 e.g. Adults ~ 20-30g
Mouse is well-conditioned.
- Vertebrae and dorsal pelvis not prominent palpable with slight pressure.

BC 4
Mouse is overconditioned.
- Spine is a continuous column.
- Vertebrae palpable only with firm pressure.

BC 5 e.g. Blobs > 50g
Mouse is obese.
- Mouse is smooth and bulky.
- Bone structure disappears under flesh and subcutaneous fat.

NOT just abdominal distention or generalized mammary gland hyperplasia ....

14

III. EXTERNAL EXAMINATION

Which is abnormal? Why?

A B

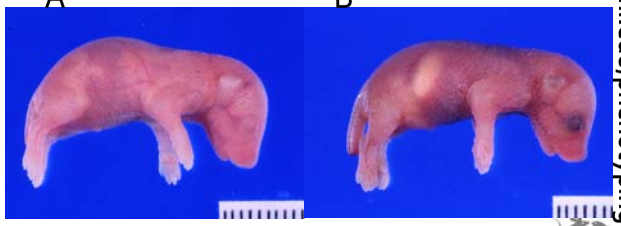

15

http://mcp.bs.jhmi.edu/phenotyping-core

III. EXTERNAL EXAMINATION

➢ 6g – 6 weeks old GEM
➢ Postweaning Death of valuable littermates.

IS this:
- An important 'Developmental delay' phenotype ?
- Spontaneous sporadic finding on various genetic backgrounds ?

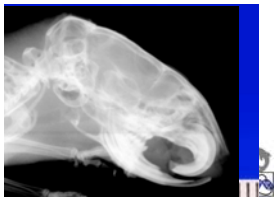

16

IV. DISSECTION (ANIMAL ORIENTATION)

➢ Always use the same orientation.
- e.g. head to the right or head to the left
  - *Are you right or left handed?*
- Same orientation and systematic approach to help recall of lesion location, esp left v right.

What color?
What sex?
WYD? Whats your diagnosis?

Agouti, Female, Vaginal prolapse

17

IV. DISSECTION (PELT REMOVAL A)

➢ Incise (or pull to open) ventral abdominal skin
- Posterior/Inguinal skin is thinner

➢ Retract (pull) skin cranially and caudally

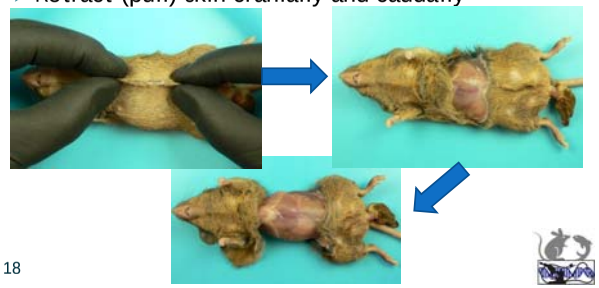

18

IV. DISSECTION (PELT REMOVAL A)

- Pull anterior/rostral skin rostrally up to forelimbs;
- Pull arms/forelimbs from pelt by holding each elbow;
- Pull anterior skin rostrally up to ears;
- Cut through external ear canals, to facilitate pelt removal (with pinnae) from head;
- Pull skin up to eyes, Cut around eyes;
- Pull skin to nose, cut trim off muzzle skin to remove pelt;
- Cut anterior skin (hoody) along ventral midline to open and lay flat on paper towel;
- *Examine for mammary, lymph node or other masses;*
- *Record abnormalities, including location & size.*

19

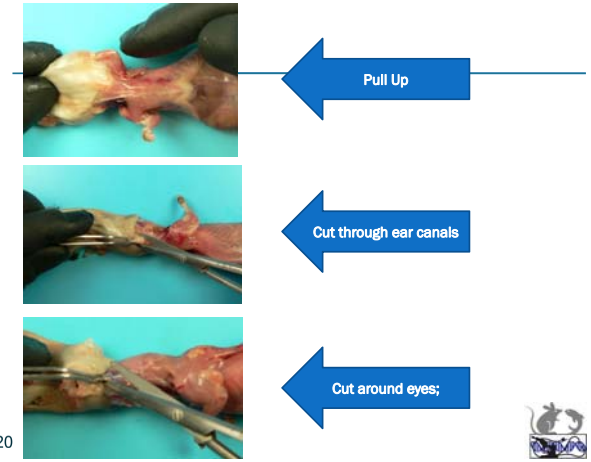

20

IV. DISSECTION DISSECTION (PELT REMOVAL A)

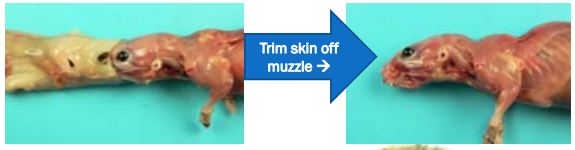

- Salivary glands should stay on mouse (not skin).

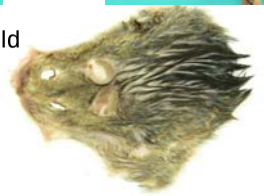

21

IV. DISSECTION (PELT REMOVAL B)

- Pull caudal/posterior skin caudally down to hind limbs;
- Pull hind limbs separately from pelt by holding femoral-tibial joint (knee);
- Pull posterior skin caudally down to tail/perineum;
- Cut through anus-perianal skin;
- Pull pelt off over tail, cutting as necessary;
- Cut posterior skin (pants) along dorsal midline;
- Lay posterior pelt flat on paper towel, for fixation;
- Note if clitoral/preputial gland came off with skin;
  - If not, find it on the animal, remove and place in cassette 9;
- Note mammary, lymph node or other masses;
- Record abnormalities, including location & size.

22

IV. DISSECTION (PELT REMOVAL B)

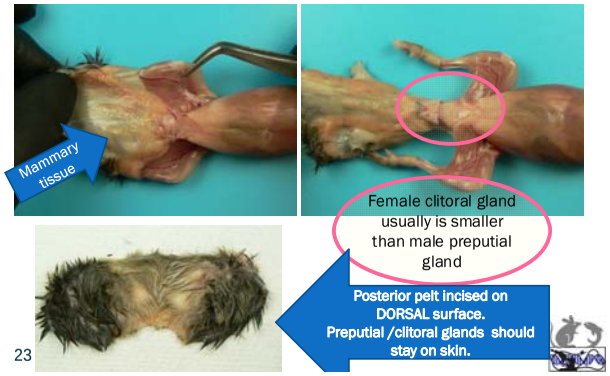

23

IV. DISSECTION: OBSERVE, EXAMINE, RECORD

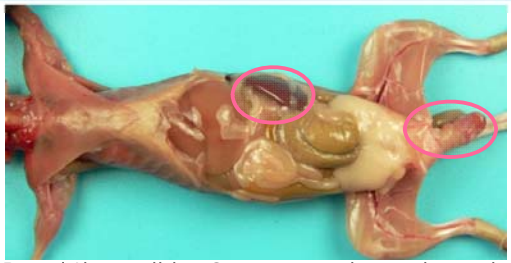

- Record Abnormalities. Comment on relevant observations.
  - **Abnormal:** Prolapse, Vaginal ~1cm; Splenomegaly wt?;
    - Pale?? Exsanguination from cardiocentesis in this case.
  - **Normal (WNL):** Adequate body fat, ingesta, fecal balls

24

IV. DISSECTION (SALIVARY GLANDS)

- Around ventral neck, from ear to ear, find 'chain' of salivary gland and lymph nodes;
- Remove entire chain by blunt dissection;
  - Start from either ear; Blunt tip fine scissors preferred;
  - Lift and cut from ear canal to ear canal, under glands;
  - Note, weigh/measure, record any abnormalities.
- Place in cassette #4;
  - Deep (dorsal) side down;
  - Close cassette;
  - Submerge in specimen container.

25

IV. DISSECTION (SALIVARY GLANDS)

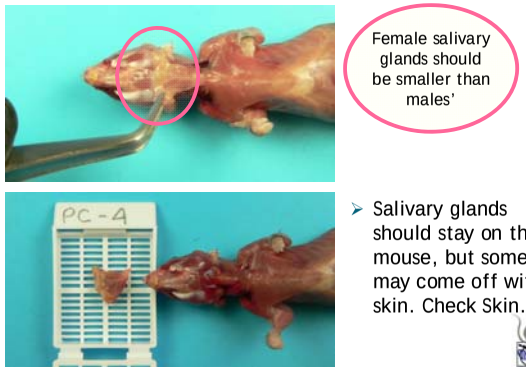

- Salivary glands should stay on the mouse, but some may come off with skin. Check Skin.

26

IV. DISSECTION (THORAX)

- Incise Peritoneum;
  - Open to expose/examine abdominal contents.
- Remove Sternum;
  - Hold **xiphoid** process w/ forceps;
  - Cut ribs on right and left sides of sternum;
  - Remove sternum; Trim ribs and excess tissue from sternum;
  - Lay sternum flat, **internal/marrow side down**, on paper towel;
  - Spread remaining ribs to open thorax and expose thoracic contents.
- Remove Thymus;
  - White soft tissue covering top of heart – 2 lobes
  - Place in **cassette #1,** close, fix.
  - **Note/record size or absence of thymus.**

27

IV. DISSECTION (THORAX)

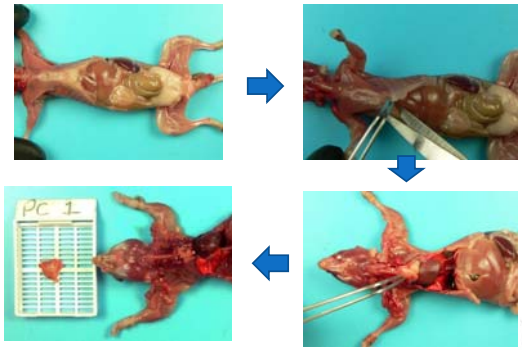

28

IV. DISSECTION: STERNUM

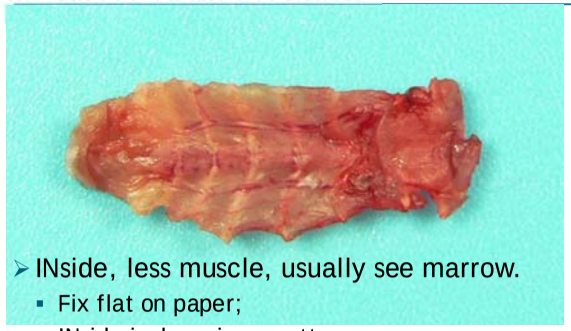

- INside, less muscle, usually see marrow.
  - Fix flat on paper;
  - INside is down in cassette.

29

IV. DISSECTION: THYMUS IN SITU

- Note/record approximate thymus size;
- Note/record absence of thymus.

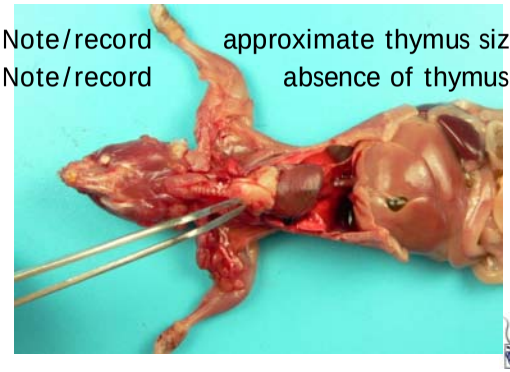

30

IV. DISSECTION: LUNG INFUSION

- Expose cervical trachea:
  - With forceps, reflect small/thin cervical muscles to expose trachea.
- Infuse lungs:
  - 3ml syringe filled w/10% NBF;
  - 20-25G needle;
  - Insert needle (bevel up) into trachea.
  - Slowly inject 10% NBF; note lung inflation.

31

IV. DISSECTION: TRACHEA EXPOSED

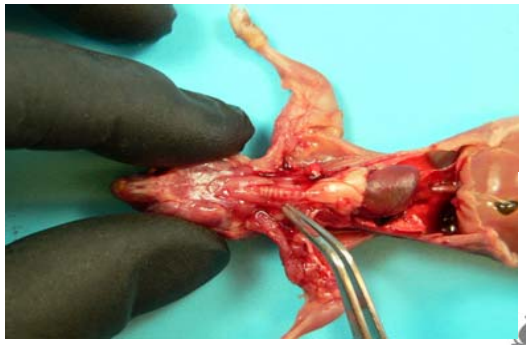

32

IV. DISSECTION: LUNG INFUSION (VIDEO)

33

http://mcp.bs.jhmi.edu/phenotyping-core

IV. DISSECTION (EN BLOC REMOVAL)

- Split mandible symphysis with scissors, and open rami laterally;
- Grasp tongue w/forceps, reflect caudally, and cut to lift tongue, larynx, trachea, esophagus;
- Remove thoracic organs en bloc by lifting plus blunt dissection near spine;
- Free thoracic contents caudally to the diaphragm;

34

IV. DISSECTION: SPLIT MANDIBLE

- Between incisors.

35

IV. DISSECTION: TONGUE

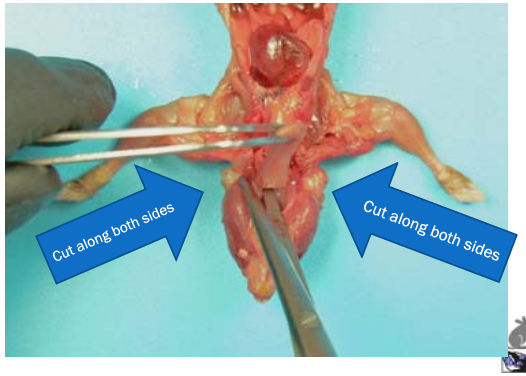

36

IV DISSECTION: REFLECT CAUDALLY (VIDEO)

37

IV. DISSECTION: AT THE DIAPHRAGM

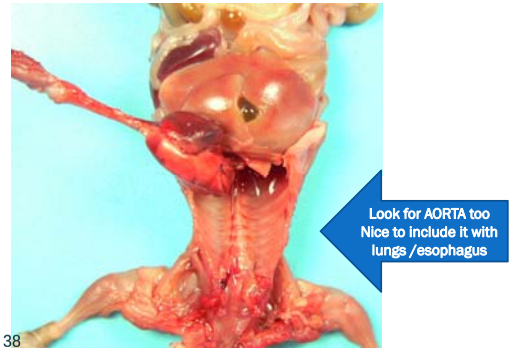

38

IV. DISSECTION (EN BLOC REMOVAL)

- Cut diaphragm to free esophagus.
- Holding cut diaphragm, lift/retract viscera caudally;
  - Identify and include small adrenals and ovaries;
  - Cut dorsal attachments near spine if necessary.
- Split pelvis by inserting closed scissors into pelvic inlet then opening them gently.
- Remove viscera completely by retracting caudally. Cut perineum as necessary.
- Tongue to anus should come out in one piece (en bloc).

39

IV. DISSECTION: FROM THE DIAPHRAGM

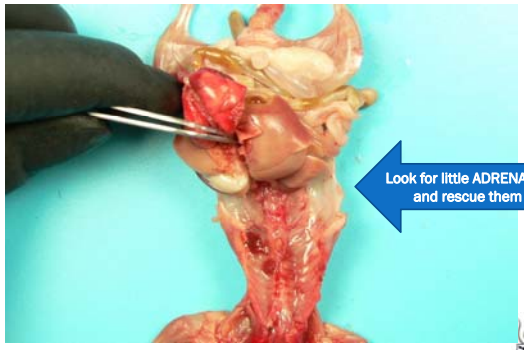

40

IV. DISSECTION: SPLIT PELVIS

- Examine, then reflect viscera laterally.
- Insert scissors closed→

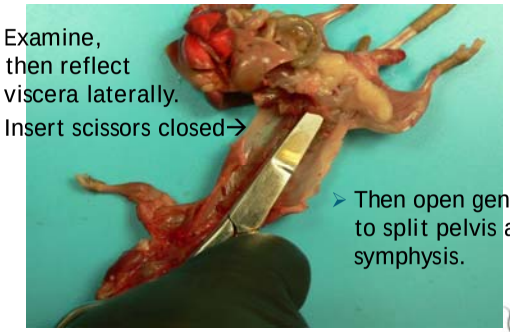

- Then open gently to split pelvis at symphysis.

41

IV. DISSECTION: PLUCK REMOVED

42

http://mcp.bs.jhmi.edu/phenotyping-core

IV. DISSECTION: VISCERA EN-BLOC

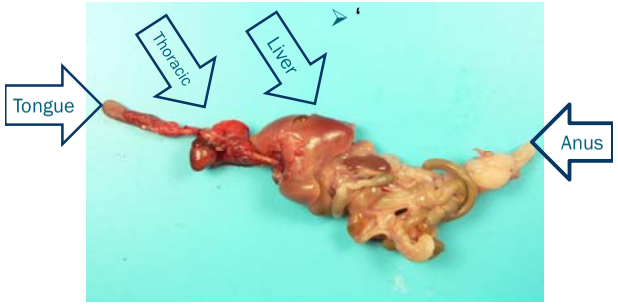

- Sometimes referred to as 'pluck' (abbatoir term).

43

IV: DISSECTION (BY ORGAN)

- Suspending viscera/pluck by the tongue, find and nick the right kidney with blade or scissors.
  - Right kidney is higher (more cranial);
  - This facilitates identification later.

Heart: Remove, weigh, fix (in toto in container).

Tongue: Cut from larynx, fix (in toto in container).

Lungs: Hold trachea, cut it free from diaphragm;
  - Lay lungs and attached larynx, trachea and esophagus dorsal side down in **cassette #2.**
  - Close cassette #2 and submerge in specimen container.

44

IV. DISSECTION: ORGANS EN BLOC (DORSUM)

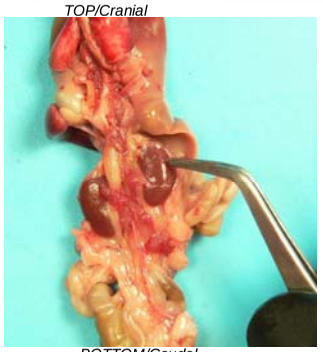

Identify
- Lungs
- Liver
- Stomach
- Spleen (big!) on left
- Adrenals (little)
- Kidneys
  - Right is higher
- Intestine and reproductive tract

45

IV: DISSECTION (BY ORGAN)

- **Heart - WEIGH IT**
- Tongue
- Lungs with
  - trachea larynx esophagus lymph nodes aorta etc

46

IV. DISSECTION: CASSETTE 2



- Lungs
  - Back down in cassette.
- Trachea
- Larynx (+ thyroids)
- Esophagus

  +/-
  - Mediastinal lymph nodes
  - Thymus remnants
  - Aorta

IV: DISSECTION (BY ORGAN)

Kidneys: Remove with **adrenals** attached:
- Remove **adrenals** etc, and place in **cassette #3;**
- Clean fat etc tissue from kidneys;
- **Weigh kidneys**; fix (intact in container).

Spleen: Remove and clean off extraneous tissue;
- **Weigh spleen**; fix (intact in container).

Liver: Remove all lobes;
- Check for small quadrate lobe with stomach;
- Remove diaphragm etc tissue from median lobe;
- **Weigh liver,** all lobes;
- Separate median & left lateral from smaller lobes; fix separated lobes intact in container.

48

IV: DISSECTION (BY ORGAN)

- **Liver**
  - Left lateral Lobe
  - Median lobe
    - Gall bladder
- **Spleen**
- **Kidneys**
  - Adrenals still attached

49

IV: DISSECTION (BY ORGAN)

Reproductive Tract: separate from GI tract;
- Check for missing pieces, ovary, bladder, etc;
  - *Also check animal remains and GI tissue mass.*
- Trim off fat etc;
- Spread out flat on paper towel; Fix intact in container.

Gastrointestinal tract (GIT):
- Starting at distal colon (fecal balls), gently elongate by stretching /pulling; (keep your fingers close together);
- Continue to the stomach; (likeliest to break at pancreas).

Pancreas/mesentery: dissect (pull gently) from GIT;
- Place **pancreas, mesentery, fat, nodes in cassette #5;** close and submerge in specimen container.

50

IV: DISSECTION: FEMALE REPRODUCTIVE TRACT

Ovaries

Uterine horns
- Abnormality: distended ~3mm diam;
- Consistent with (cw): hydrometra, mucometra
- Cause? Obstruction by vaginal prolapse?

Urinary Bladder
- Ventral to cervix, vagina et

IV: DISSECTION: MALE REPRODUCTIVE TRACT

- (Different mouse)

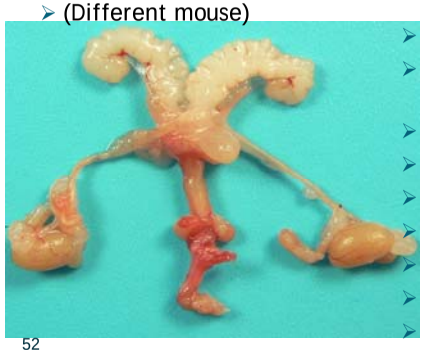

- Seminal vesicles
- Coagulating gland
- Bladder
- Prostate
- Vas deferens
- Epididymis
- Testes
- Urethra
- Penis

52

IV: DISSECTION: GI TRACT

Identify
1. **Stomach**
2. **Cecum**
3. **Fecal Balls**

53

IV: DISSECTION: G.I. TRACT (VIDEO)

54

IV: DISSECTION: GI TRACT

- Pancreas, Mesentery
- Elongated stripped GIT

Slide 5
- Pancreas, Mesentery
  - Fat, lymph nodes

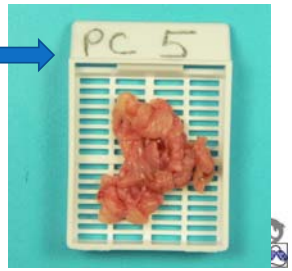

IV: DISSECTION (GI TRACT)

- **GI tract infusion, fixation**
  - With 3ml syringe, infuse entire gut with 10% NBF at multiple sites from stomach to colon
  - Fix (intact, in container)
- GI tract: Swiss roll options
  - **Closed**: roll closed intestine into 2-3 cassettes
  - **Open**: open intestine, flush clean with fixative, examine, count/measure lesions, roll into cassettes.
  - *Practice this BEFORE you need it…*
  - *Which method is best for your project?*

56

IV: DISSECTION: (GI TRACT INFUSION) (VIDEO)

57

IV: DISSECTION: (PARTS ON PAPER)

1. **Skin**
2. **Sternum**
3. **Reproductive Tract**

- Examine, measure lesions, abnormalities.
- Fix these on paper; remove excess paper;
- Submerge flat in fixative, or wrap/roll gently in paper for immersion fixation;
- **CLEAN UP.**

58

IV-V: DISSECTION-DECAL (BONEY PARTS)

1. **Head:** Sever/separate from cervical spine;
   - Submerge in Formical-4® ~ 24 hr.
2. **Legs, spine:** Save in fix, or decalcify.
   - **Hind Legs** with pelvis:
     - Separate from spine, cut caudal to rostral near spine;
     - Should NOT crunch if separating cleanly from spine.
   - **Arms** with scapula:
     - Separate from thorax – should NOT crunch (except tiny clavicle).
   - **Spine**: Cervical, thoracic, lumbar, sacral;
     - Trim off ribs, usually tail.

59

V. DECALCIFY / DEMINERALIZE

- Sever/separate Head from spine:
  - Cut at flexion = atlanto occipital joint;
  - Should NOT crunch through the joint.

END OF NECROPSY

1. **Labeled container** of saved fixed tissues +
   - Labeled Cassettes:
     - 1,2,3,4,5 (or more) contain tissues;
     - Include lesions in labeled cassettes.
   - On paper – skin, sternum, repro:
     - May be useful to include lesions; label in pencil.
2. **Weights**: Body, heart, spleen, liver, kidneys
   - Additional tissues – before or after fixation?
3. **Report**: with weights, measurements.

61

VI. TRIMMING TISSUES INTO CASSETTES

Aims:
- Reproducible systematic evaluation of as much as possible on relatively few slides.
- Tissues dissected and trimmed reproducibly to facilitate comparisons between animals & studies.

- Understood:
  - Customize protocol for special needs of different projects.
  - For tox evaluations:
    - http://reni.item.fraunhofer.de/reni/trimming/

62

VI. TRIMMING TISSUES INTO CASSETTES

1. Heart, thymus, tongue, sternum
2. Lungs, trachea, thyroid/parathyroid, esophagus
3. Kidneys, adrenals
4. Salivary glands, cervical lymph nodes
5. Pancreas, mesentery, mesenteric lymph nodes
6. G.I. tract
7. Liver, spleen
8. Reproductive tract, urinary bladder, distal rectum
9. Skin, clitoral/preputial gland (+/- Decal leg)
10. Head – decalcified

63

VI. TRIMMING TISSUES INTO CASSETTES

Cassette 1

- **Thymus** - already in cassette – both lobes.
- **Sternum** - Marrow (in)side down in cassette.
- **Tongue** - Section Longitudinally
  - → half in cassette. (Xsections for some studies)
- **Heart** - Hemi-sect sagitally
  - To identify all chambers;
  - Both halves in cassette.

Close cassette and re-submerge.

64

CASSETTE 1

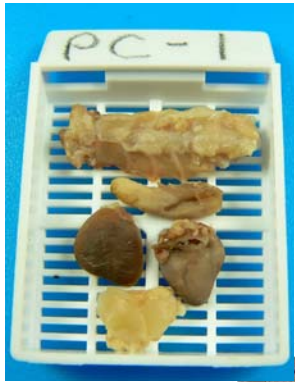

65

JH#1 EXAMPLE

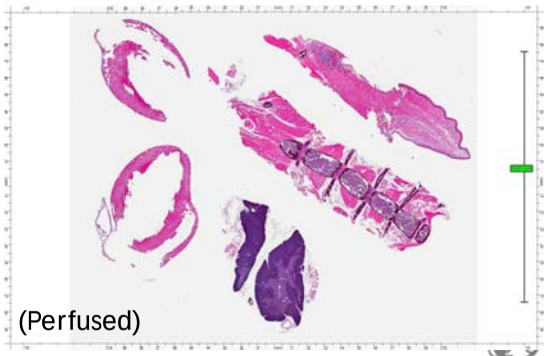

66

VI. TRIMMING TISSUES INTO CASSETTES

Cassette 2

- **Trachea, larynx, thyroid:**
  - Remove excess tissue with forceps;
  - Identify thyroids below larynx;
  - Transect trachea below (distal to) thyroid
  - Place larynx/thyroid into cassette
    - Hoping for cross section
- **Lungs** - Entire: dorsal side down in cassette.

Close cassette and re-submerge.

67

CASSETTE 2

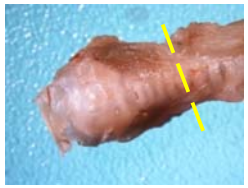

68

JH#2 EXAMPLE

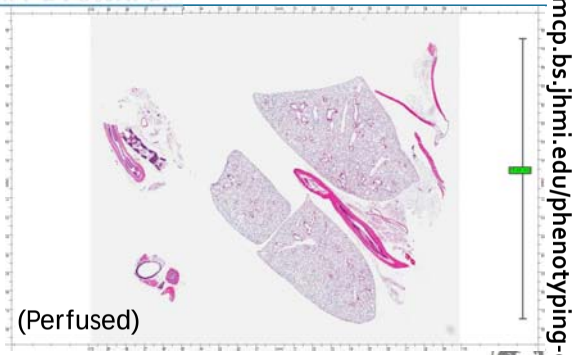

69

VI. TRIMMING TISSUES INTO CASSETTES

Cassette 3

- **Adrenals** – trim off fat (or not)
  - Males' usually are smaller than females';
  - Use biopsy foam, tea bags or special cassettes, for small adrenals <2mm, or special needs.
    - CONSULT HISTO LAB PREFERENCES.
- **Right kidney** → 1 or 2 cross sections
- **Left kidney** → 1 or 2 Longitudinal sections
  - Both halves of both kidneys, Cut side down.
  - [cross sections of both kidneys for certain studies]

Close cassette and re-submerge.

70

CASSETTE 3

71

JH #3 EXAMPLE

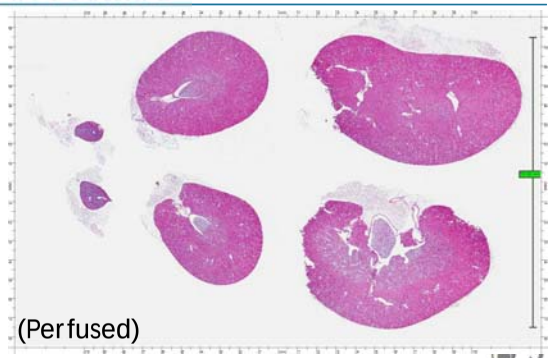

72

VI. TRIMMING TISSUES INTO CASSETTES

Cassette 4

- **Salivary glands and cervical – submandibular lymph nodes**
- *Should be in cassette already.*
  - Submandibular Glands
    - *Males' should be bigger than females'*
  - Sublingual Glands
  - Parotid Glands

    +/- Exorbital Lacrimal Glands

    +/- Mammary glands

73

JH#4: SALIVARY GLANDS, ASSOCIATED NODES

Which is **Male** ?

A or B ?

1. **Submandibular**
2. **Sublingual**
3. **Parotid**
   - **(exorbital lacrimal)**
4. **Lymph nodes**

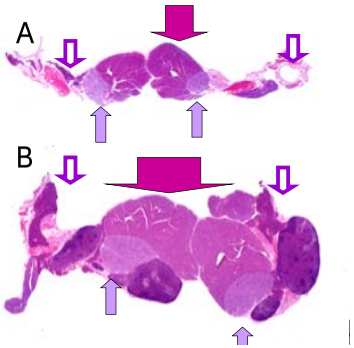

VI. TRIMMING TISSUES INTO CASSETTES

Cassette 5

- **Pancreas, mesentery** and lymph nodes
- *Should be in cassette already*

75

JH#5 EXAMPLE

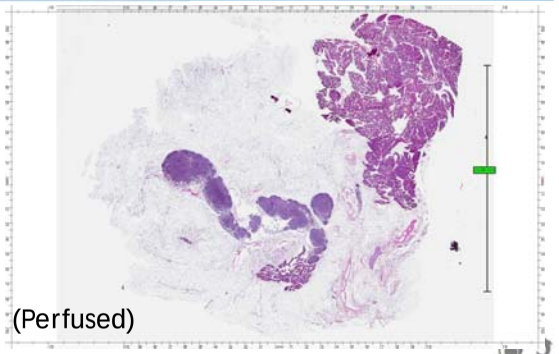

76

VI. TRIMMING TISSUES INTO CASSETTES

Cassette 6: GI Tract

- **Stomach** – separate (cut) from duodenum
  - Section to include squamous and glandular portions (**0**-shape).
- **Small intestine:** duodenum, jejunum and ileum
  - 1-2 sections 4-5mm long → **o** on cross section - from each region
- **Cecum**
  - Cut **U**-shape section from tip.
- **Proximal Colon** (note diagonal stripes = mucosal folds)
  - 2 sections 4-5mm long → **O** on cross section
- **Distal Colon** (fecal balls usually)
  - 2 sections 4-5mm long → **o** on cross section

Close and submerge cassette.

77

CASSETTE 6



- Too many pieces for most histo labs …
- $$$

78

JH#6 EXAMPLE

- Too many pieces; Content removed ☹

79

SWISS ROLL OPTIONS…

- **'Closed'**
  - **I like gut content**
- **'Open' allows gross assessment of lesions**
  - **Then assess selected lesions**

80

SWISS ROLL OPTIONS

- Closed roll →
  - ☺ Content
  - ☺ Exudate
  - ☺ Pseudomembrane
  - ☺ Intact mucosa
- Open roll
  - ☹ prettier?…

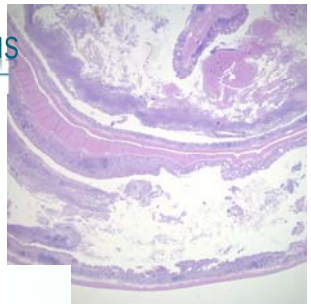

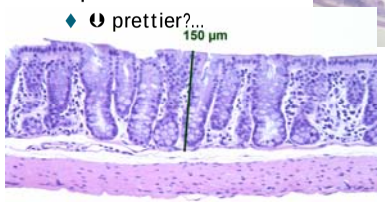

GIT CONTENT CAN BE INFORMATIVE….

- Microbiome
  - = microbial genomes
- Microbiota
  - = all the agents
- NOT just bacteria!
  - Viruses fungi protists metazoan parasites;
- NOT just feces!
  - Important variations by site…

82

CECUM – 'NORMAL' CONTENT?

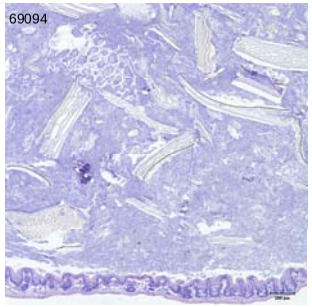

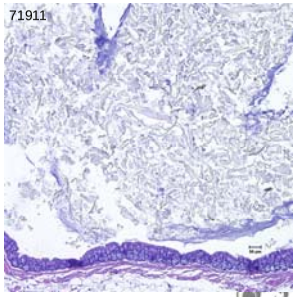

83

ANOTHER OPTION…

- GIT Opened, fixed, gross lesions documented
- Histology on lesions
  - Tumor? GIN ?
  - Crypt/gland loss
  - Squamous metaplasia

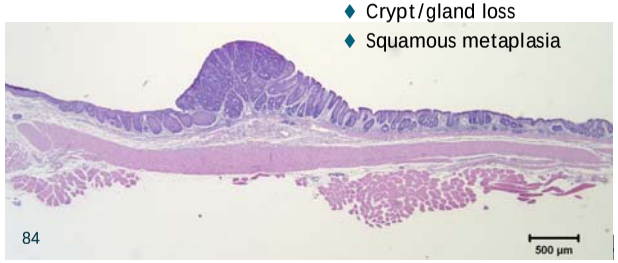

84

VI. TRIMMING TISSUES INTO CASSETTES

Cassette 7

- **Liver** – median + lateral lobe sections:
  - Median lobe → ~4mm wide section, include gall bladder;
    - Cut above 'crease' & just below the gall bladder;
  - Left lateral lobe → ~4mm wide section;
    - Cut diagonally from hilus to edge to get nice long section.
  - Lesions – include any lesions in these or other lobes.
- **Spleen** - Hemisect longitudinally/sagitally
  - Put 1 or both sections in cassette
- 2 liver sections + 1-2 spleen sections normally fit in one cassette

85

CASSETTE 7



86

JH#7 EXAMPLE

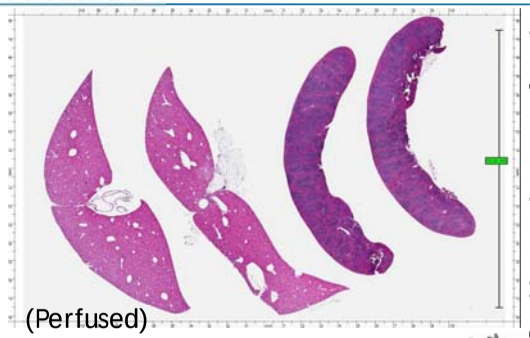

87

http://mcp.bs.jhmi.edu/phenotyping-core

VI. TRIMMING TISSUES INTO CASSETTES

Cassette 8 – Reproductive Tract

- Small, male or female reproductive tract fits intact into cassette;
  - Ensure that all organs are in one plane – foam can help.
- If necessary, separate and trim representative sections of gonads, accessory sex glands, urinary bladder and rectum.
- Prostate or other protocols (MMHCC or Simons & al. 2010) may require special dissections.

88

CASSETTE 8

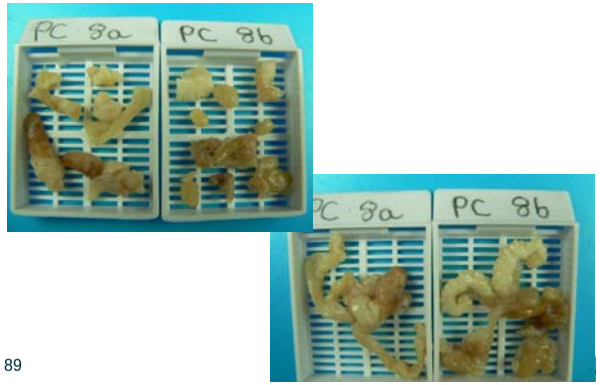

89

VI. TRIMMING TISSUES INTO CASSETTES

Cassette 9

- **Skin** - Cut strips 4mm wide, parallel to hair growth, of Representative areas e.g.
  - **Craniofacial- dorsal neck** - to include periocular, periauricular, perioral skin
  - **Ventral - inguinal** – to include preputial or clitoral gland, external orifices
  - **Lesions**
- **Leg** - decalcified - include here?
  Close cassette & submerge.

90

CASSETTE 9

- Haired Skin sections best when block is sectioned parallel to section
  - roughly parallel to hairs too
- *Too long, too many in this cassette.*

91

JH#9 EXAMPLE

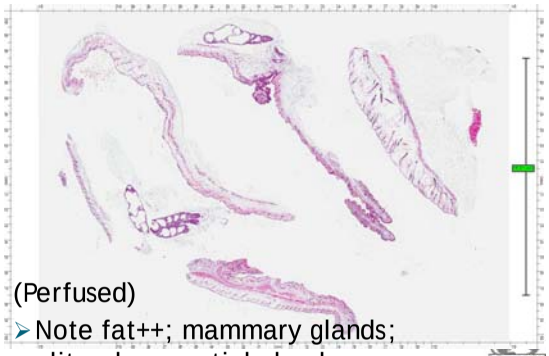

(Perfused)

- Note fat++; mammary glands; clitoral, preputial glands.

92

VI. TRIMMING TISSUES INTO CASSETTES

Cassette 10 - Head - Decalcified

- External ear openings & eyes are primary landmarks.
- Lambdoid & coronal sutures also are useful
- A right handed prosector usually holds the nose in the left hand and cuts/sections with the right hand, starting with the most posterior/caudal sections and progressing anteriorly/rostrally.

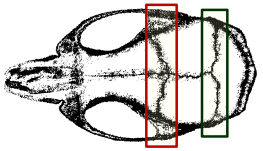

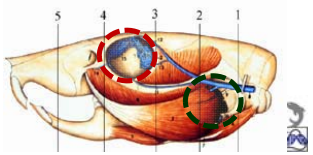

CASSETTE 10

1st section → Cerebellum - brainstem:

- Cut transversely caudal to ear canals, near/at bregma & lambdoid suture;
- Place FRONT/ROSTRAL/ANTERIOR side **down** in cassette.

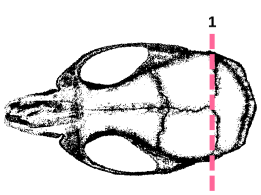

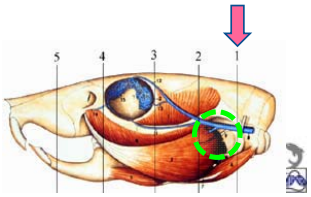

CASSETTE 10

2nd section → Ears; hippocampus; midbrain; pituitary:

- Next cut rostral to ear canals; between coronal and lambdoid sutures (closer to coronal suture);
- Place FRONT/ROSTRAL/ANTERIOR side **down** in cassette.

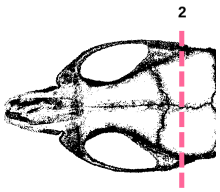

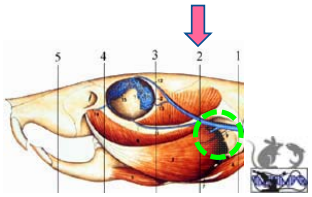

CASSETTE 10

3rd section → Forebrain, cortex, (hippocampus) TMJ, molar teeth:

- Next cut is caudal to eyes, near coronal suture.
- Place BACK/CAUDAL/POSTERIOR side **down** in cassette.

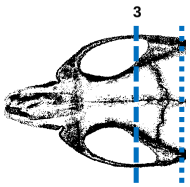

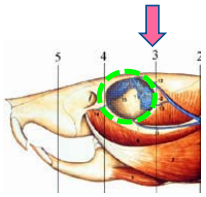

CASSETTE 10

4th section → Eyes, Harderian glands, olfactory lobes, molar teeth:

- Next cut is just rostral to eyes;
- Place BACK/CAUDAL/POSTERIOR side **down** in cassette.

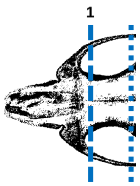

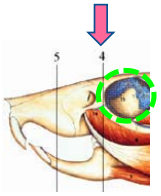

CASSETTE 10

5th section: Nose turbinates, incisors:

- Remaining nose may fit in cassette OR
- Cut 3-5mm rostral to previous cut;
- Place BACK/CAUDAL/POSTERIOR side **down** in cassette.

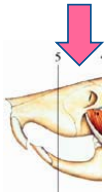

CASSETTE 10

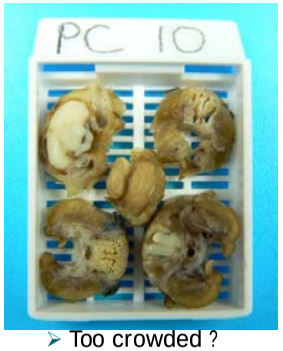

1. Cerebellum medulla
   - FRONT/anterior down
2. Ears hippocampus, midbrain, pituitary
   - FRONT/anterior down
3. Forebrain, molars
   - BACK/posterior down
4. Eyes, olfactory bulbs
   - BACK/posterior down
5. Nose
   - BACK/posterior down

- Too crowded ?
  - trim off mandible.. Or → 2 cassettes.

99

JH#10 EXAMPLE

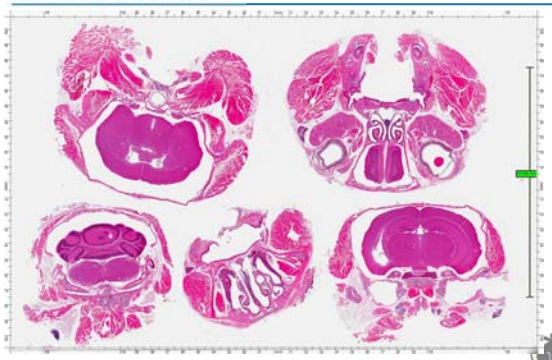

100

MICE

- Stroke…

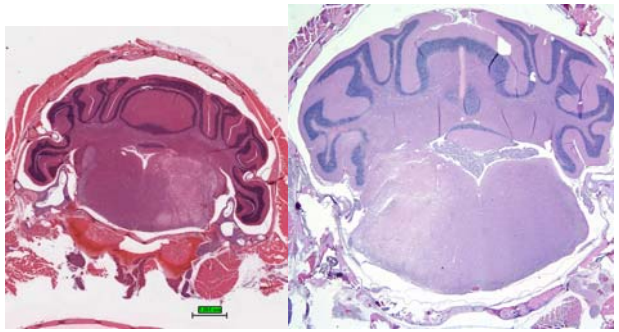

MICE

- Gram stain

MICE

- Otitis

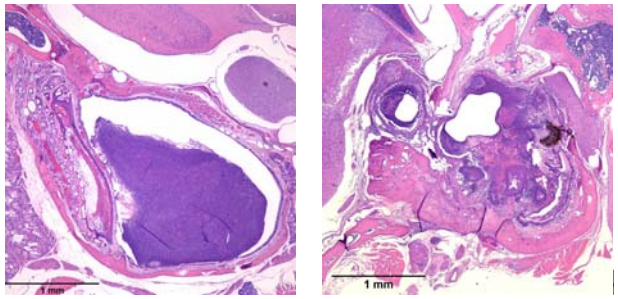

41086

- Eyeballs? Consider
  - Enucleation;
  - Fekete's fixative Acid alcohol protocol; 24-48hr fix.

67189 *nu/nu* OR 67188 FVB/N?

- Standard decal protocol is informative diagnostic
- WYD = what's your diagnosis/es?

A. Cataract
B. Keratitis
C. Periocular debris
D. Retinal degeneration cw *rd1/rd1*

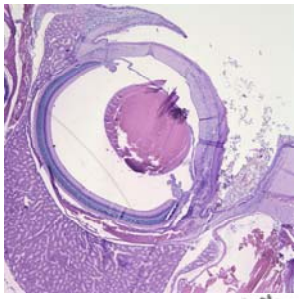

http://mcp.bs.jhmi.edu/phenotyping-core

67189 *nu/nu* OR 67188 FVB/N?

- Standard decal protocol is informative diagnostic
- WYD = what's your diagnosis/es?

A. Cataract
B. Keratitis
C. Periocular debris
D. Retinal degeneration cw *rd1/rd1*

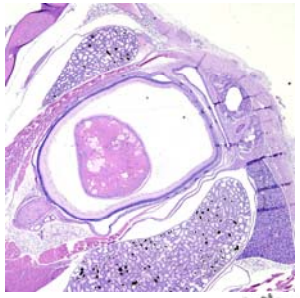

70274 NSG 41086 WNL

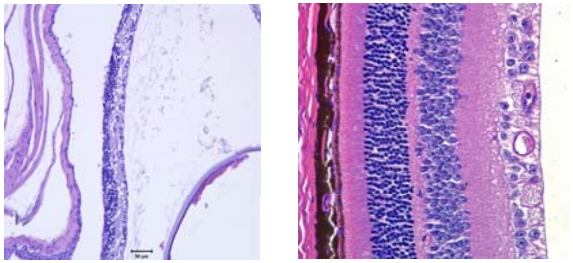

+ Perinatal irradiation

MIDLINE SECTIONS CAN BE INFORMATIVE

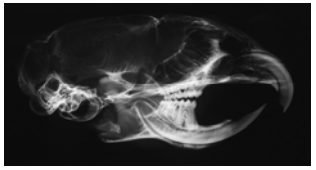

- Fresh /fixed hemisection
- Midline section between incisor
  - Cut/crunch sphenoid bone ONLY
- Or Fix/decal, then hemisection for histology.

COD/CCOD RX/TECHNIQUE

- Bleeding
  - Retrorbital sinus
  - Facial Vessels
- Injections
  - Retrorbital sinus →
  - Vasculature?
  - Intracranial?
  - Intraocular?

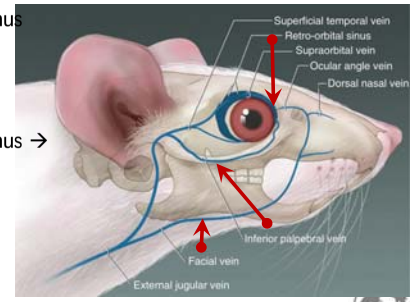

Yardeni et al. 2011 – retroorbital injection technique
https://www.ncbi.nlm.nih.gov/pmc/articles/PMC3158461/

COD RETROORBITAL? INJECTION

- Intracranial? →
- Intraocular?

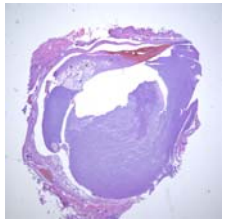

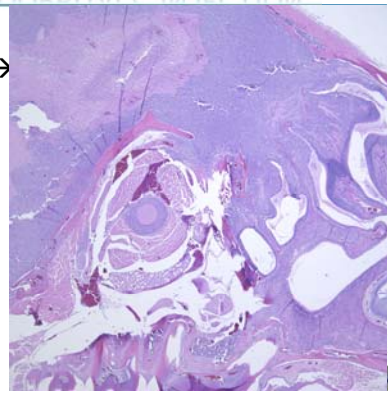

SPINE DECAL

- Formic acid fix +decal

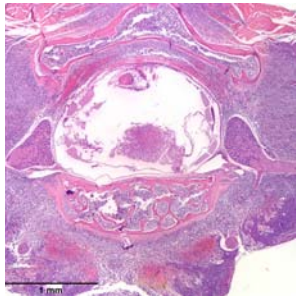

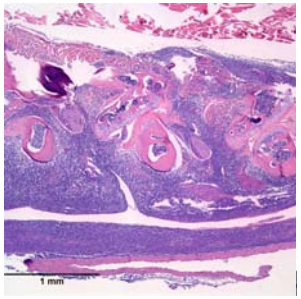

60371 NOG DYING

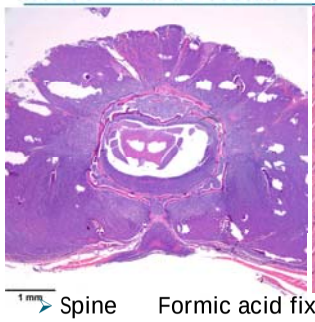

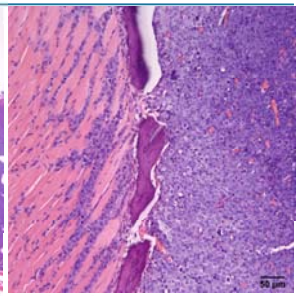

- Spine Formic acid fix + decal
- NOG NSG NRG NCG: No lymphocytes ???
- Lymphoma/Leukemia

MOUSE

- Tibia
- Rx?

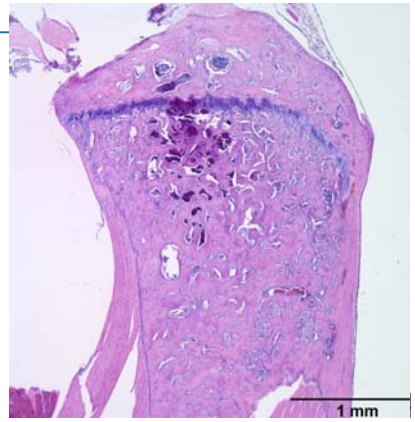

NOT JUST MICE .... 58327 – BUDGIE

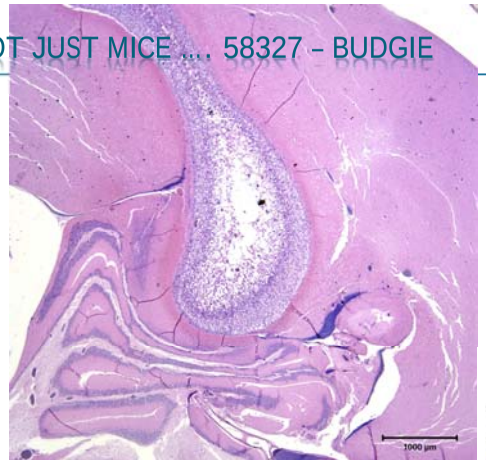

58327 – BUDGIE

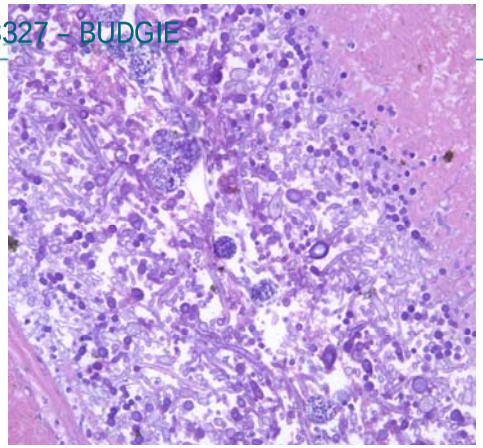

BAT

- Rhinitis

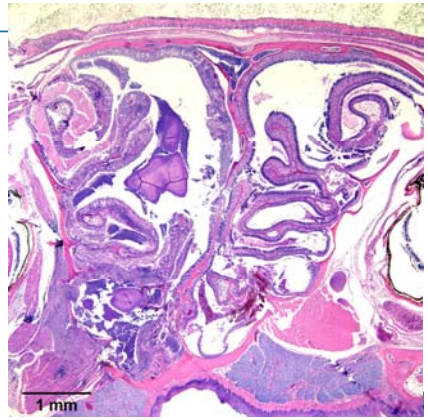

BAT

- Rhinencephalitis

CARDINAL

- Otitis

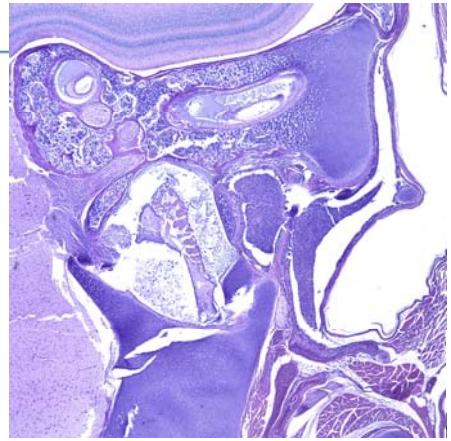

BLACK BOX PATHOLOGY?

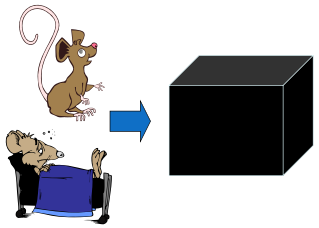

Πλεασε συβμιτ τηε ωηολε μουσε, ωιτη χορρεχτ ανδ υσεφυλ γενετιχ, χλινιχαλ, ανδ εξπεριμενταλ ινφορματιον. Μουσε βιτσ, μιχιχλεσ, ποορλψ/ιμπροπερλψ φιξεδ & ροττεν σπεχιμενσ τηατ ηασε υνδεργονε μορε τηαν 1 χηανγε οφ στατε τενδ το φρυστρατε τηε πατηολογιστ ανδ ψιελδ υνσατισφψινγ ρεσυλτσ φορ τηε συβμιττερ. Ιν Συμ: Γαρβαγε ιν, γαρβαγε ουτ!

119

~~BLACK BOX PATHOLOGY?~~

Up to everyone to ask questions, learn more about models and pathology…

Please submit the whole mouse, with correct and useful genetic, clinical, and experimental information; OR dissect collect usefully. Rotten mouse bits, micicles, poorly/ improperly fixed & rotten specimens that have undergone more than one change of state frustrate the pathologist and yield unsatisfying results for the submitter.

In Sum: Garbage IN, Garbage OUT!

120



JHU Phenotyping Core
Mouse Perfusion

N Forbes, C Brayton 2019 rev

1

Aims of perfusion:

- Uniformly perfuse all tissues with fixative delivered via the vascular system;
- Achieve excellent tissue preservation;
- Prevent/preclude post mortem cell/tissue decomposition (autolysis), and minimize artifacts of decomposition and handling that interfere with analysis of histology specimens.

2

Overview

- Blood is flushed from vasculature
- Fixative is delivered
  - Injected slowly through left ventricle
  - Driven through the systemic circulation and allowed to drain from the incised right atrium
- Success indicators
  - Muscle contraction
  - Blanching of liver
  - Mouse should be stiff
  - Excellent histology ☺

3

Materials

1. Down draft table or fume hood;
2. PPE (gloves, mask, eye protection);
3. Two 20ml syringes;
4. Saline-Heparin flush (10units/ml);
5. 10% Neutral Buffered Formalin;
6. Vacutainer Butterfly collection set 25G x ¾ x 12in;
7. Absorbent paper towels;
8. Single edge blade 1.5in;
9. Dissecting tools
   - Iris scissors, forceps, fine spring scissors.

4

Saline Heparin flush

- Saline heparin lock flush 
- Or
  - 1000 unit heparin vial
    - 1ml heparin diluted in 100ml 0.9% saline
  - 5000 unit heparin vial
    - 1ml heparin diluted in 500ml 0.9% saline

5

Materials

1. Scissors:
   - Big coarse (skin, bone);
   - Fine for RA right atrium.
2. Hep/saline:
   - 20ml syringe, labeled.
3. Fixative:
   - 20ml syringe, labeled.
4. Blade;
5. Butterfly infusion set
   - 25g
   - 3/4 inch

Method

1. Fill 20ml syringe with saline-heparin;
2. Fill 20ml syringe with 10% NBF.
3. Open Butterfly pack, cut ~3mm off of plastic needle guard;
   - 'cuff' prevents needle from piercing through heart.

4. Attach blood collecting set to saline-heparin syringe and prime/fill tubing.

7

Method

5. Euthanize animal, weigh & record weight in grams

6. Optional: Remove pelt at costal margin reflect rostrally
7. Cut ribs to expose thoracic content
   - Retain sternum if you plan to evaluate sternum marrow

8

Method (continued)

8. Incise (nick) **right atrium** using the fine spring scissors.

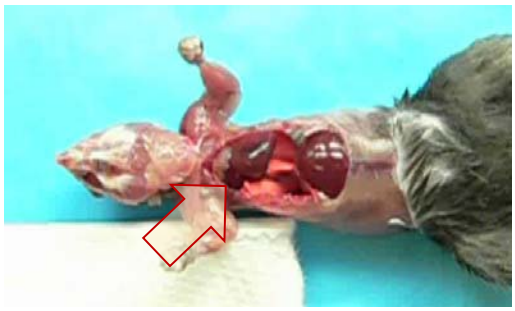

9

Method (continued)

9. Carefully insert needle (attached to saline heparin syringe) into **left** ventricle.
10. Slowly inject saline heparin
    - Usually ~5-10ml is sufficient.
    - Blood & tissues should become pink or pale.



10

Method (continued)

11. Without retracting needle, remove the Hep/saline syringe and attach fixative (10%NBF) syringe.
12. **Slowly**, over > 1 minute, inject fixative
    - Watch for muscle tremors;
    - Total body stiffening indicates good perfusion;
    - Usually ~5-10ml is sufficient.

11

10% NBF Perfusion (video)

12

(rev 2019)

ANATOMIC PATHOLOGY SUBMISSION

MCP# _____ **P**

To be completed by Submitter: _____ Contact _____

Date _____ Charge # _____ Investigator _____

Species _____ Strain/Geno _____ Mutant **Y☐/ N☐** Animal ID# _____

Source _____ **JH** Room # _____ Color **BL☐/ Ag☐/ AL☐/** _____

Sex **F☐/ M☐** Age _____ Found Dead **Y☐/ N☐** Euth **CO2☐/ CD☐ /** _____

Additional Requests (complete separate forms): **CBC/Diff☐** **Clin Chem☐** **Urinalysis☐**

Micro/Parasit: **Serology☐** **Culture☐** **PCR☐** **Parasit Fur☐** **Tape☐** **Float☐** **PCR☐**

Behav☐ **QNMR☐** **Other:** _____

Bleed Site: **Retroorbital☐/ Facial☐/ Saphenous☐/ Tail☐/ Cardiac☐/**_____ Volume:_____ **ml.**

History and Clinical Signs (Include correct nomenclature, background strains, genetic manipulations/ mutation(s), generations of backcrossing, experimental manipulations including bleeding, special diets, drug treatments e.g. Baytril, Ivermectin, Fenbendazole; reason(s) for submission; clinical signs):

_____

To be completed by Prosector: _____ Research ☐/ Diag ☐/ Teaching ☐

Body Condition: **1☐(emaciated)** **2☐** **3☐(normal)** **4☐** **5☐(morbidly obese)**

Body Wt (g)	Liver (g)	Spleen(g)	♥(g)			

Gross Findings (Include weights/measurements, diagrams whenever possible.):

ID Tags/#'s (save with tissues: _____ Ear Punch: **R**  **L**

_____

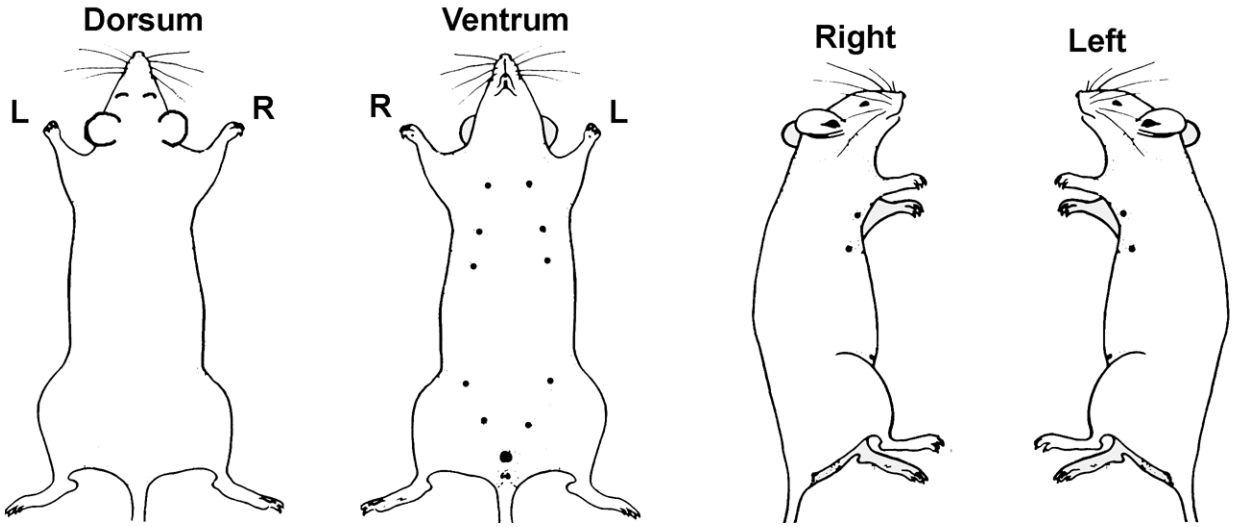

Anatomic Pathology Trimming/Dissection

Prosector _____ **MCP#** _____ **P**

Cassette #	Tissues (Slides 1-10 = standard necropsy)
☐ 1	♥Heart☐+ Thymus☐ [+/- sternum☐ diaphragm☐ tongue☐ soleus☐]
☐ 2	Lung ☐entire, formalin-infused + thyroid/trachea ☐
☐ 3	Kidneys – right/cross☐, left /long ☐+ Adrenals☐
☐ 4	Submandibular + parotid salivary glands + L nodes ☐
☐ 5	Pancreas + Lymph nodes (mesenteric chain + any enlarged (→ 6a,b,c etc)
☐ 6	GI (Stom, Duod/panc, Ileum, Cecum, Prox colon, Rectum)
***or* 6a**☐ b☐ c☐	for GI Swiss Roll – open ☐ closed ☐
☐ 7	Liver (L Lateral+ Median Lobe/G bladder) + Spleen
☐ 8	Female (Uterus + Ovaries, Vagina/bladder/rectum)
or ☐ 8	Male (Testes/Epi, Sem ves, Bladder/prostate /rectum)
☐ 9	Skin – dorsal neck + inguinal (mammary + clitoral/preputial gl)
☐ 10	Decal Head ears (pituitary, thalamus, hippocampus, cortex), eyes (olfactory lobes, molars), nose (olfactory + respiratory, incisors), cerebellum, medulla
☐ 11	Decal hind limb (knee + tarsus), Sternum - *or Leg on 9* ☐ *sternum on 1* ☐
☐12(a,b,c…)	Spine *- or spine on 9* ☐ *with skin*
☐ 13	Lesions:
☐____.	

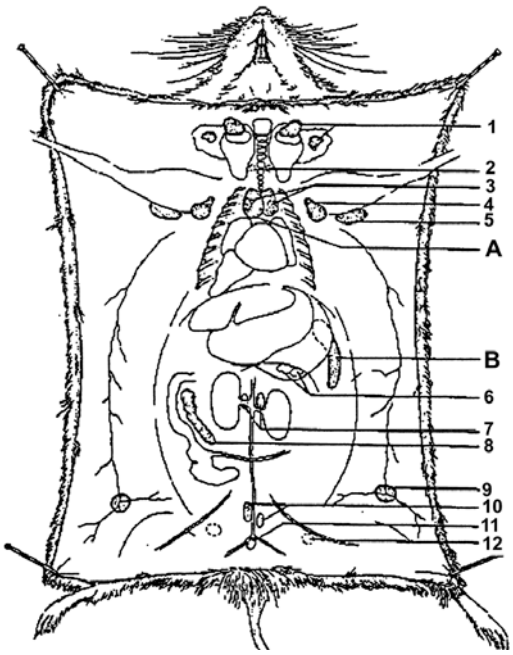

Mouse Lymph Nodes adapted from Dunn 1954
(+Van den Broeck, et al. 2006)

1. Superficial cervical (or *mandibular*) Nodes
2. Deep cervical node
3. Mediastinal Nodes
4. Axillary Nodes
5. Brachial Nodes

A. Thymus
B. Spleen

6. Pancreatic (or *pancreaticoduodenal*) Node
7. Renal Nodes
8. Mesenteric (or *jejunal*) Nodes
9. Inguinal (or *iliac*) Node
10. Lumbar Nodes
11. Sacral Nodes
12. Sciatic Nodes

NS Popliteal Node – Behind Knee

Additional Findings (continued from front page)

_____
_____
_____
_____
_____
_____
_____
_____

Submitted: ___/___/___ **Completed:** ___/___/___ **#Slides:** ____

Wednesday Laboratory Sessions 1,2

Welcome + Instructions

Good afternoon. My name is Nadine. I work with Dr. Brayton.
This is a brief orientation of expectations.

Each Laboratory will have gowns, gloves, masks and tools, and worksheets.

All rooms should have wifi access, should you wish to link to the website and download the lab manual, or pdf's to view during the lab. Each room also should have a projector to view the relevant PPTs.

After demonstrations (SHIRPA hemoccult and bleeding (facial and cardiocentesis) urine collection and testing, teams will go to workstations.

SHIRPA: As a team, perform the tests in order, on several mice, and record results.

Facial blood collection: Less experienced participants should pair with team lab instructors for blood collections. You may request anesthesia for your mouse before attempting facial bleed.
Cardiocentesis: Anesthesia is required. A lab instructor will anaesthetize mice for you.
After cardiocentesis, the mouse should be dead (anesthetic overdose, and exsanguination). Confirm death with lab instructor. You may practice cervical dislocation with instructor assistance.

Glucometry: Use EDTA blood (purple top) from the facial bleed, or cardiocentesis. Put one drop into weigh dish then take it and your glucose strip to the glucometer. With the white computer strip facing you, press strip into top slot, wait 8-10 seconds, touch strip tip to blood drop. Record results.

Body weight: estimate weight; then weigh with weighing machine. Record results.

Deceased mice: Confirm death with lab instructor before disposal in designated red bag for the room.

Hemoccult (Guiac): Save fresh feces from each mouse in a clean paper towel. Conduct Hemoccult AFTER working on live mice.

Please turn in your work sheets – please note (Check box) if you want it back.
<u>Graduate students who are taking the course for credit</u> MUST complete and turn in work sheets for each lab session. THEY SHOULD ALSO INITIAL THE ATTENDANCE LIST FOR EACH SESSION.

Finally Clean up your work area, properly discarding biomaterials and sharps.

<u>Again</u>

1) Sign in; Team introductions, including mice
2) SHIRPA,
3) Blood collections: Facial; anesthesia; cardiocentesis; Confirm death of mouse.
4) Glucometry
5) Estimate weight and weigh mouse;
6) Hemoccult
7) Repeat (time permitting)
8) Turn in worksheet
9) Clean up

JHU Mouse Pathobiology and Phenotyping Short Course

Check Box if you want this page back ☐

Check Box if you are a Graduate student taking ME 680.712 for credit ☐

YOUR NAME: _____

LAB 1 (Wed)

Behavioral Phenotyping Level 1 Screening

(from JW 1/06)

Scoring Key: 0=zero 1=slow or reduced 2- normal 3=hyper

*Condition score: 1=emaciated 2= low body fat 3=normal 4= excessive body fat 5=grossly obese

Animal #:	Wild Type Hemi -/-
DOB/Age:	Sex M F
Weight (g):	Fur Color:
Condition Score*:	

EMPTY CAGE (2 mins.)			Escape	Y	N
			Exploring	0....1.....2.....3	
			0= <1 side 1=< 1 circuit 2=multiple circuits 3=frantic		
Gait abnormal?	Y	N			
Posture abnormal	Y	N			
Freezing	Y	N	Digging	0.....1.....2.....3	
Wild Running	Y	N	Grooming	0.....1.....2.....3	
Stereotypies	Y	N	Rearing	0.....1.....2.....3	

PHYSICAL EXAM Dorsal Ventral

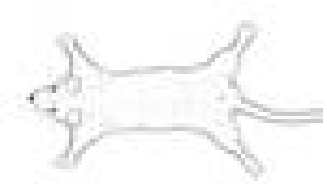

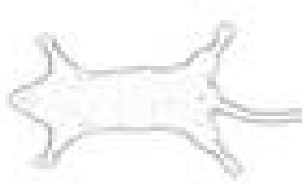

DRAW
Bald patches/abnormalities

Bald patches	Y.....N	Piloerection	Y.....N
Physical abnormality	Y.....N	Whisker damage	Y.....N
Body Tone	0....1....2....3	Whisker response	0....1....2....3
Petting Escape	0....1....2....3	Ear twitch	0....1....2....3
Passivity	0....1....2....3	Palpebral reflex	0....1....2....3
Trunk Curl	0....1....2....3	Forelimb Place	0....1....2....3
Righting	0....1....2....3	Right leg withdraw	0....1....2....3
Visual Placing	Y N	Biting	0....1....2....3
Reach touch	Y N	Clicker	0....1....2....3
		Grip strength < 60 sec.	> 60 sec.

Notes: _____

_____

_____

Check Box if you want this page back ☐

Check Box if you are a Graduate student taking ME 680.712 for credit ☐

YOUR NAME: _____

LAB 2 (Wed)

Specimen Collection

Survival Bleed

Blood Volume: _____ul

Post bleed mouse activity:

- ☐ normal
- ☐ slow
- ☐ dead

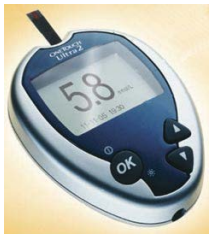

Glucose:

- ☐ Accuchek _____mg/dL
- ☐ One Touch _____mg/dL

Which do you prefer ? ☐ Accuchek ☐ One Touch

Why ?

Fecal Occult Blood:

Control (feces + blood) turned blue ☐ ,**or** did not turn blue ☐

Test specimen (just feces) turned blue ☐**, or** did not turn blue ☐

Terminal Bleed (Cardiocentesis)

☐ Successful ☐ Unsuccessful

Blood Volume: _____ul

Mouse Weight **Guestimate** _____ **Weighing Machine** _____

Blood: _____g Total: _____g

Note 1ml of blood weighs ~1.06g)

JHU Mouse Pathobiology and Phenotyping Short Course

Check Box if you want this page back ☐

Check Box if you are a Graduate student taking ME 680.712 for credit ☐

YOUR NAME: _____

Lab 3 (Thu)

Gross Examination (Necropsy)

Terminal Bleed (Cardiocentesis)

☐ Successful ☐ Unsuccessful

Blood Volume: _____ul

Urinalysis (if available)

Specific Gravity (SG) Refractometer _____

Chemstrip: SG ____; Gluc ___; prot ___;

***** Please write your name on Container (70%EtOH – not formalin)

Gross Findings: draw & describe – indicate size whenever possible

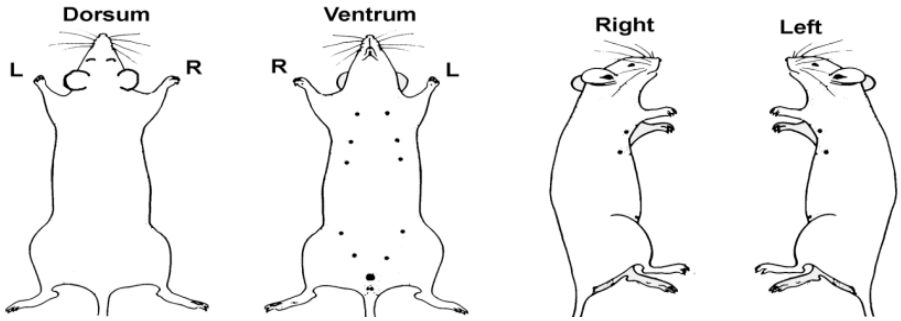

WNL	NOT	WT	Tissue / Disposition – describe abnormalities
			Pelt on paper (cranial-ventral; inguinal-dorsal); immerse/submerge in fix
			Salivary glands in cassette 4
			Thymus → cassette 1 – note size: ~_____mm
			Lungs infused
			Pluck removed **(mandible & pelvis split)**
			Tongue → cassette 1
		g	**Heart*** weigh; immerse/submerge intact in fix
			Lungs (dorsal side down), trachea, esophagus → cassette 2
			Adrenals → cassette 3
		g	**Right kidney* (nicked)** and **left kidney***; weigh → cassette 3
		g	**Spleen*** weigh; immerse/submerge (intact) in fix
		g	**Liver*** weigh; separate lobes; immerse/submerge in fix
			Reproductive tract – spread on paper; immerse/submerge in fix
			G.I. elongate, infuse; immerse/submerge in fix
			Pancreas & mesentery → cassette 5
			Head, spine, right leg → decal solution
			* Normally heart, kidneys, spleen, liver are weighed

JHU Mouse Pathobiology and Phenotyping Short Course

Check Box if you want this page back ☐

Check Box if you are a Graduate student taking ME 680.712 for credit ☐

YOUR NAME: _____

Lab 4 Fri

Trimming (into cassettes OR arrange on paper)

Cassette	Tissue, trim procedure – Describe abnormalities
☐ 1	**Heart** – Hemisect to expose all four chambers); include both halves usually. **Tongue** – longitudinal or cross section. ** **Sternum** – position in cassette inside (marrow side) down; trim off excess tissue. ****Thymus** – already in cassette.
☐ 2	**Larynx** – to include **thyroid / parathyroid** glands as cross or long section (lab preference). **Lungs** – Intact, all lobes, Dorsal side down (with some trachea/esophagus). Aorta – nice to capture these in sections.
☐ 3	**Right kidne**y – cross section midline to include pelvis papilla. **Left Kidney** – section longitudinally near midline aiming to include pelvis papilla. Include all sections if there is space in cassette. **Adrenals** – as is; OR foam or method preferred by histo lab for small specimens.
☐ 4	****Salivary glands** with **lymph nodes;** already in cassette.
☐ 5	****Pancreas** and **mesentery** (+ Lymph nodes); already in cassette.
☐ 6	**GI Tract –** cross sections to include duodenum, jejunum, ileum, proximal and distal colon; section tip/end of cecum; section stomach to represent non-glandular and glandular portions. **GI Tract – Nothing done if Swiss rolled into cassettes at collection.
☐ 7	**Liver** – **Median lobe** section to include gallbladder between left and right parts. **Left lateral lobe** from hilus to edge. **Spleen –** section longitudinally; Include both halves when there is room; cross sections preferred for some studies.
☐ 8	**Reproductive**: intact in cassette, OR trim to include representative sections of all structures.
☐ 9	**Skin**: 3-4mm strips section parallel to hair growth. Don't crowd cassette. Craniofacial skin – include muzzle-eyelid-neck. Inguinal skin –include clitoral or preputial gland, perineum. [practice trimming arranging leg to fit in cassette]
☐ 10	**Decal head:** Cut on caudal and rostral side of ear canal → section 1,2. Cut on caudal and rostral side of eyes→ sections 3,4. Nose = section 5 (may have to trim to fit in cassette). First two (rear) sections placed in cassette rostral (front) side down. Final (front) sections placed in cassettes caudal (back) side down.
☐	<u>Other Lesions</u>